www.cosmoderma.org

ScientificScholar®
Knowledge is power
Publisher of Scientific Journals

CosmoDerma

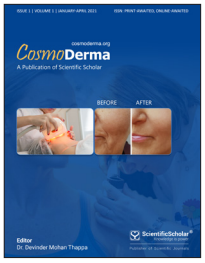

Images/Instrument in Dermatology/Dermatosurgery

Supernumerary nipples through the lens of a dermoscope

Resham Vasani[1], Kavya Baddireddy[2]

[1]Department of Dermatology, Bhojani Clinic, Mumbai, Maharashtra, [2]Department of Dermatology, Dr. Kavya The Skin and Hair Clinic, Visakhapatnam, Andhra Pradesh, India.

***Corresponding author:**
Resham Vasani,
Bhojani Clinic, Earth Classic,
Babasheb Ambedkar Road,
Matunga, Mumbai 400019,
Maharashtra, India.

mailreshamvasani@gmail.com

Received: 11 July 2025
Accepted: 12 August 2025
Published: 08 October 2025

DOI
10.25259/CSDM_112_2025

Quick Response Code:

A 17-year-old male undergoing acne evaluation had three asymptomatic brown abdominal lesions with thick hair, unchanged since childhood [Figure 1a-c]. Similar lesions were noted in his mother and sister. Systemic examination was unremarkable.

Dermoscopy showed a pigmented network with a central cleft (right lesion), a central scar-like area (upper left lesion), and cobblestone-patterned light-colored angular specks (lower left lesion) [Figure 2a-c]. A diagnosis of supernumerary nipples (SN) was made based on clinical location, familial occurrence, and dermoscopic features.

SNs (1–6% incidence) are congenital anomalies affecting both sexes, typically forming along milk lines or ectopically on the chest, abdomen, thighs, or arms. Inheritance may be sporadic or familial.[1] Systemic associations, particularly genitourinary anomalies, are notable and carry an increased malignancy risk.[2] Associations with genetic syndromes such as Turner syndrome, trisomy 8, trisomy 2p, Fleisher's syndrome, Char syndrome, and neurofibromatosis type 1 have been documented.[3]

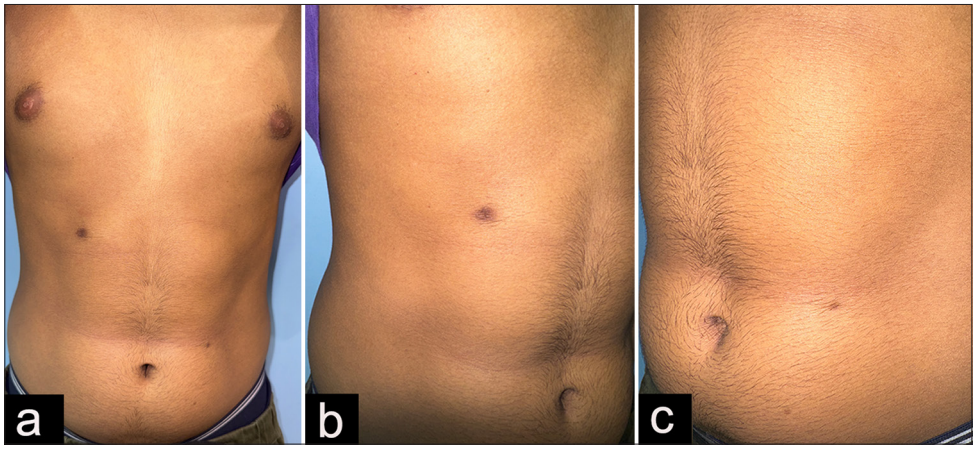

Figure 1: (a) Brown lesions one on right and two on the left of midline on the abdomen, (b) 0.5 × 0.5 cm brown raised lesion located on the right milk line, (c) a 0.25 × 0.25 cm brown papule just above the umbilicus on the left milk line, a small brown macule seen below the umbilicus on the left milk line, and with 1-2 darker and thicker hairs compared to the surrounding vellus hairs observed in both lesions.

This is an open-access article distributed under the terms of the Creative Commons Attribution-Non Commercial-Share Alike 4.0 License, which allows others to remix, transform, and build upon the work non-commercially, as long as the author is credited and the new creations are licensed under the identical terms.
©2025 Published by Scientific Scholar on behalf of CosmoDerma

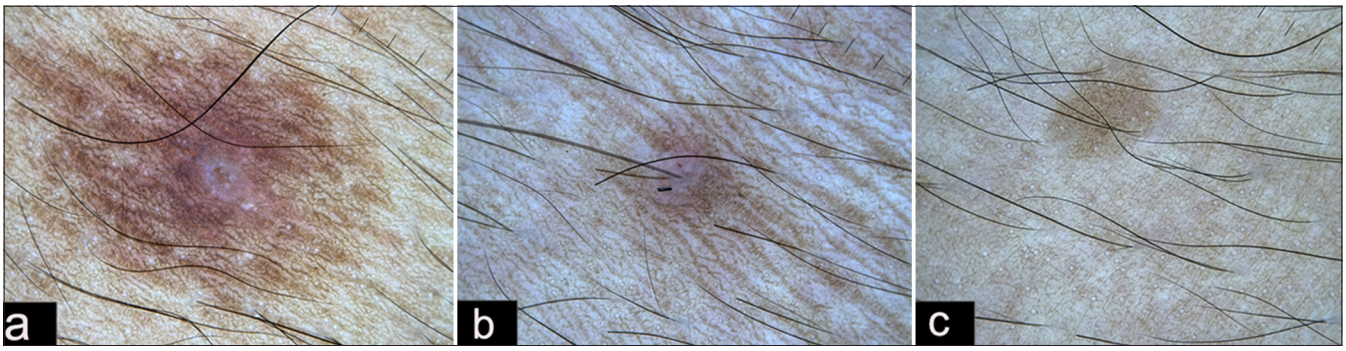

Figure 2: (a) Dermoscopy showing interconnected dark brownish thin lines forming a pigment network on a diffuse tan background, with a small cleft-like feature at the center, (b) central structureless white scar-like area with prominently thick, dark hair compared to surrounding vellus hair, (c) light-colored angulated specks clustered together in a cobblestone pattern (Dermlite DL4; ×10, polarized mode).

Dermoscopy helps differentiate SN from dermatofibromas and nevi. Recognizing SN as a genodermatosis with malignancy risk, especially in ectopic cases, is crucial.

Ethical approval: Institutional Review Board approval is not required.
Declaration of patient consent: The authors certify that they have obtained all appropriate patient consent.
Financial support and sponsorship: Nil.
Conflicts of interest: There are no conflicts of interest.
Use of artificial intelligence (AI)-assisted technology for manuscript preparation: The authors confirm that there was no use of artificial intelligence (AI)-assisted technology for assisting in the writing or editing of the manuscript and no images were manipulated using AI.

REFERENCES

1. Brown J, Schwartz RA. Supernumerary nipples: An overview. Cutis 2003;71:344-6.
2. Grimshaw EC, Cohen PR. Supernumerary nipple and seminoma: Case report and review of polythelia and genitourinary cancers. Dermatol Online J 2013; 19:4.
3. McKay M, Coad R. A brother and sister with breast cancer, BRCA2 mutations and bilateral supernumerary nipples. Ann Transl Med 2017;5:106.

How to cite this article: Vasani R, Baddireddy K. Supernumerary nipples through the lens of a dermoscope. CosmoDerma. 2025;5:108. doi: 10.25259/CSDM_112_2025