

Innovations

A novel use of a blunt hypodermic needle for cleaning of plicated nail gutter

Muhammed Mukhtar¹

¹Department of Dermatology, Mukhtar Skin Centre, Katihar, Bihar, India.



***Corresponding author:**

Muhammed Mukhtar,
Department of Dermatology,
Mukhtar Skin Centre, Katihar,
Bihar, India.

drmmukhtar20@gmail.com

Received: 25 January 2026
Accepted: 20 February 2026
Published: 26 March 2026

DOI
[10.25259/CSDM_20_2026](https://doi.org/10.25259/CSDM_20_2026)

Quick Response Code:



Video available on:
[https://doi.org/10.25259/
CSDM_20_2026](https://doi.org/10.25259/CSDM_20_2026)

PROBLEM

A plicated nail is a unilateral pincer nail that looks like an ingrown nail and is painful. To relieve discomfort quickly, trim the ingrown lateral nail, clean the gutter, and put on wicking or padding. However, there is no perfect device accessible in the clinic to clean keratinous debris in the deep and curved nail gutter. We cleaned the gutter with a hypodermic needle that was readily available.

SOLUTION

A 23 or 24 G hypodermic needle was used. The beveled portion of the needle is broken to make it blunt. After that, the nail gutter is cleaned using a needle to remove the keratinous debris [Figure 1a]. Following trimming, the gutter is sealed with fevikwik glue to harden the gutter floor and blunt the freshly growing lateral nail [Figure 1b and Video 1]. Thus, the blunt hypodermic needle may be a cost-effective aseptic device for cleaning the deep-seated bent or plicated nail

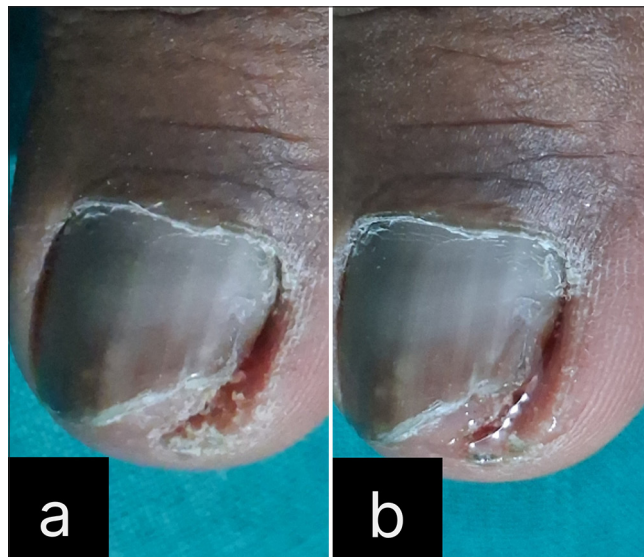
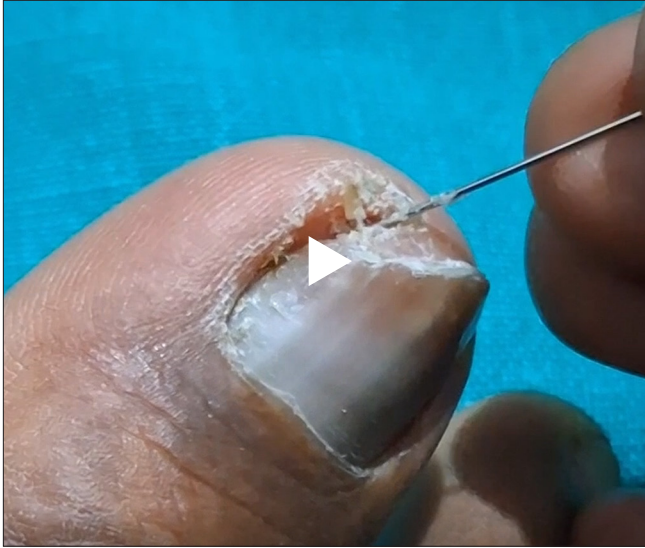


Figure 1: (a) Plicated lateral nail plate is trimmed, and (b) the cleaned nail gutter is splinted with fevikwik.

This is an open-access article distributed under the terms of the Creative Commons Attribution-Non Commercial-Share Alike 4.0 License, which allows others to remix, transform, and build upon the work non-commercially, as long as the author is credited and the new creations are licensed under the identical terms.

©2026 Published by Scientific Scholar on behalf of CosmoDerma



Video 1: The hypodermic needle is used to clean the gutter.
Video available on: https://doi.org/10.25259/CSDM_20_2026

gutter keratinous debris before palliative chemical splinting of a plicated nail. This splinting is a wonderful alternative for passive patients who do not want to be operated on,

but it needs to be done every 2–4 months depending upon recurrence of symptoms of plicated nail.

Ethical approval: Institutional Review Board approval is not required.

Declaration of patient consent: The authors certify that they have obtained all appropriate patient consent forms. In the form, the patient has given consent for their images and other clinical information to be reported in the journal. The patient understands that the patient's names and initials will not be published and due efforts will be made to conceal their identity, but anonymity cannot be guaranteed.

Financial support and sponsorship: Nil.

Conflicts of interest: There are no conflicts of interest.

Use of artificial intelligence (AI)-assisted technology for manuscript preparation: The authors confirm that there was no use of artificial intelligence (AI)-assisted technology for assisting in the writing or editing of the manuscript and no images were manipulated using AI.

How to cite this article: Mukhtar M. A novel use of a blunt hypodermic needle for cleaning of plicated nail gutter. *CosmoDerma*. 2026;6:35. doi: 10.25259/CSDM_20_2026