

Visual Treats in Dermatology

White islands in the sea of red

Aravind Sivakumar

Department of Dermatology, Velammal Medical College, Madurai, Tamil Nadu, India.



***Corresponding author:**

Aravind Sivakumar,
Department of Dermatology,
Velammal Medical College,
Madurai, Tamil Nadu, India.
aravinddermat@gmail.com

Received : 20 January 2023
Accepted : 13 February 2023
Published : 20 February 2023

DOI
10.25259/CSDM_22_2023

Quick Response Code:



A 9-year-old boy was brought by the parents with complaints of fever and rash for 5 days duration. It was accompanied by generalized malaise and arthralgia. The rash started around the face and then spread to involve the trunk and extremities. There was no bleeding history, headache, or abdominal pain alongside the rash. Examination revealed that the presence of diffuse erythematous maculopapular rash over the trunk, and extremities with few islands of sparing noted between [Figure 1a]. There were petechiae which were noted in the oral cavity, conjunctiva, flexures, and pressure areas. The Rumpel-Leede test was positive suggested by the presence of ecchymosis along the Sphygmomanometer cuff sites and cubital fossa [Figure 1b]. Hence, a diagnosis of dengue hemorrhagic fever (DHF) was made and was serologically confirmed. Dengue fever is a mosquito-borne arboviral infection that can have an incubation period of 5–8 days. The cutaneous manifestation can vary based on the age group and severity usually starting with facial flushing progressing to diffuse maculopapular rash. Some individuals might show areas of sparing alongside the maculopapular rash which is referred to as “white islands in a sea of red.” This clinical clue can

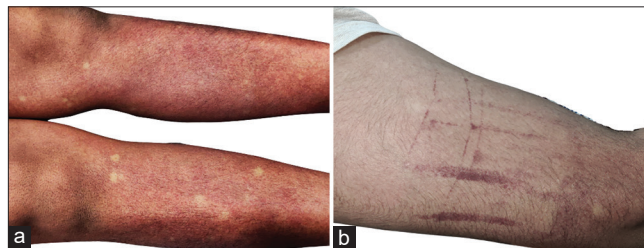


Figure 1: (a) Diffuse erythematous maculopapular rash with areas of sparing appearing as “white islands in the sea of red.” (b) Positive Capillary fragility test or Rumpel-Leede phenomenon.

be very helpful in the diagnosis of DHF in the absence of seropositivity in the early stages.^[1]

Declaration of patient consent

The authors certify that they have obtained all appropriate patient consent.

Financial support and sponsorship

Nil.

Conflicts of interest

There are no conflicts of interest.

REFERENCES

1. Thomas EA, John M, Kanish B. Mucocutaneous manifestations of dengue fever. Indian J Dermatol 2010;55:79-85.

How to cite this article: Sivakumar A. White islands in the sea of red. CosmoDerma 2023;3:36.