

Visual Treats in Dermatology

Dilated pore of winer on scar: An unusual presentation

Konsam Nirupama Devi¹, Gurumayam Chitralkha Devi¹

¹Department of Dermatology, Venereology and Leprosy, All India Institute of Medical Sciences, Rishikesh, Uttarakhand, India.



***Corresponding author:**

Konsam Nirupama Devi,
Department of Dermatology,
Venereology and Leprosy,
All India Institute of
Medical Sciences, Rishikesh,
Uttarakhand, India.

nirupama.konsam@gmail.com

Received : 22 July 2022

Accepted : 03 August 2022

Published : 25 August 2022

DOI

10.25259/CSDM_71_2022

Quick Response Code:



A 29-year-old woman presented with an asymptomatic reddish skin lesion with a blackish, rounded lesion on the left breast for the past 1 year. Cutaneous examination revealed an ill-defined, erythematous, non-tender, firm plaque of size 4 × 3 cm in diameter, with a rounded, comedo-like lesion with keratin plug, on the upper outer quadrant of the left breast [Figure 1a]. Skin biopsy revealed haphazard fascicle of dense collagen in dermis suggestive of scar tissue and markedly dilated follicular infundibulum filled with keratinous material and acanthotic epidermis suggestive of the dilated pore of Winer [Figure 1b]. It is important to distinguish dilated pore of Winer, a benign follicular tumor, from pilar sheath acanthoma, trichofolliculoma, and comedones.^[1] Considering the presence of scar in our patient, keratin material was removed using

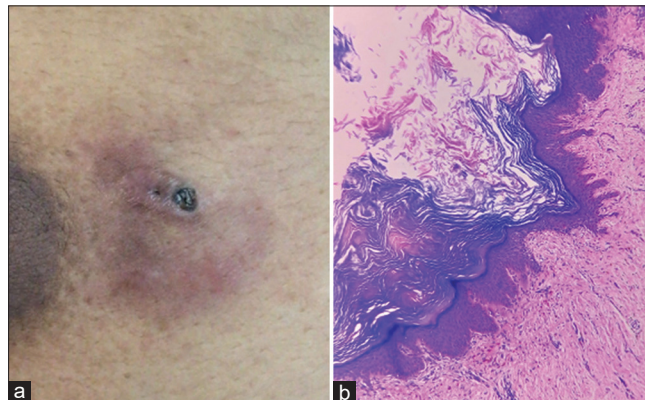


Figure 1: (a) Ill-defined, erythematous, firm plaque measuring 4 × 3 cm in diameter with a rounded, comedo-like lesion measuring 3 × 3 mm in diameter on the left breast. (b) Histology: Markedly dilated follicular infundibulum filled with keratinous material and acanthotic epidermis (H&E stain, ×10).

a comedone extractor, although surgical excision is usually curative. After the removal of the keratinous plug, topical silicone gel application was advised for scar management.

Declaration of patient consent

Patient's consent not required as patient's identity is not disclosed or compromised.

Financial support and sponsorship

Nil.

Conflicts of interest

There are no conflicts of interest.

REFERENCE

1. Tellechea O, Cardoso JC, Reis JP, Ramos L, Gameiro AR, Coutinho I, *et al.* Benign follicular tumors. *An Bras Dermatol* 2015;90:780-96; quiz 797-8.

How to cite this article: Devi KN, Devi GC. Dilated pore of Winer on scar: An unusual presentation. *CosmoDerma* 2022;2:65.