

Visual Treats in Dermatology

Pearls on the hip

Arunachalam Narayanan

Department of Dermatology and STD, Jawaharlal Institute of Postgraduate Medical Education and Research, Puducherry, India.



***Corresponding author:**

Arunachalam Narayanan,
Department of Dermatology
and STD, Jawaharlal Institute
of Postgraduate Medical
Education and Research,
Puducherry, India.

narayanan359@gmail.com

Received : 06 January 2023

Accepted : 10 January 2023

Published : 20 January 2023

DOI

10.25259/CSDM_7_2023

Quick Response Code:



A 6-year-old boy presented with multiple umbilicated and pearly papules on the hip [Figure 1a]. Dermoscopy revealed a central poly-lobular white amorphous structure [Figure 1b]. Tzanck smear of the central white core demonstrated basophilic intracytoplasmic bodies [Figure 1c]. Based on the clinical, dermoscopic, and Tzanck smear, we made a final diagnosis of molluscum contagiosum and treated them using curettage. Molluscum contagiosum is caused by molluscum contagiosum virus and presents as small, firm, dome-shaped, and pearly papules with central umbilication. Dermoscopy of molluscum contagiosum reveals poly-lobular white to yellow amorphous structure with a peripheral crown of linear or branched vessels.^[1] Tzanck smear demonstrates Henderson-Paterson bodies which appear as ovoid and basophilic bodies with a

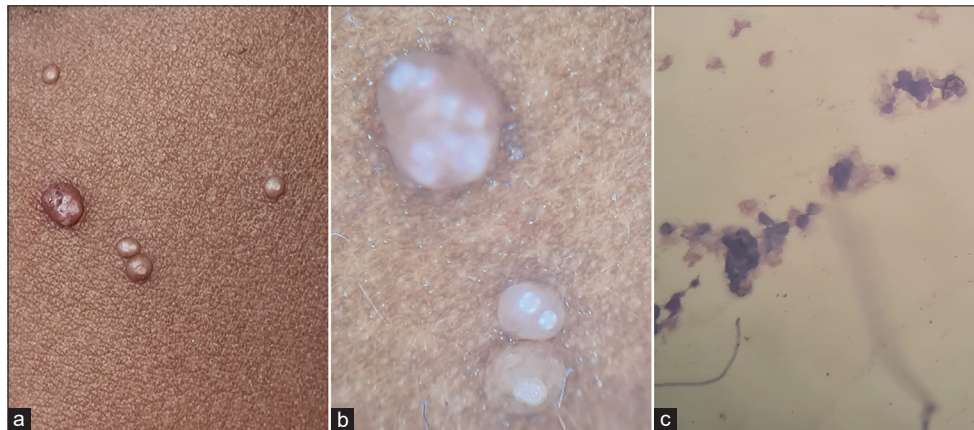


Figure 1: (a) Multiple, dome-shaped, umbilicated, and pearly papules seen on the hip. (b) Dermoscopy demonstrating poly-lobular white amorphous structure (DL200, ×10, polarized, non-contact). (c) Tzanck smear of the central white core demonstrating basophilic intracytoplasmic bodies (Giemsa Stain, 40X).

This is an open-access article distributed under the terms of the Creative Commons Attribution-Non Commercial-Share Alike 4.0 License, which allows others to remix, transform, and build upon the work non-commercially, as long as the author is credited and the new creations are licensed under the identical terms.

©2023 Published by Scientific Scholar on behalf of CosmoDerma

hyaline homogenous structure. Treatment for molluscum contagiosum includes curettage, electrocautery, cryotherapy, and trichloroacetic acid.

Declaration of patient consent

Patient's consent not required as patient's identity is not disclosed or compromised.

Financial support and sponsorship

Nil.

Conflicts of interest

There are no conflicts of interest.

REFERENCE

1. Bakos RM, Leite LL, Reinehr C, Escobar GF. Dermoscopy of skin infestations and infections (entomodermoscopy)-Part II: Viral, fungal and other infections. *An Bras Dermatol* 2021;96:746-58.

How to cite this article: Narayanan A. Pearls on the hip. *CosmoDerma* 2023;3:17.