

Visual Treats in Dermatology

Dermoscopy of plantar wart

Vishal Gaurav¹ , Ishan Agrawal¹

¹Department of Dermatology and Venereology, Maulana Azad Medical College, New Delhi, India.



***Corresponding author:**

Vishal Gaurav,
Department of Dermatology
and Venereology, Maulana
Azad Medical College,
New Delhi, India.
mevishalgaurav@gmail.com

Received: 27 June 2024
Accepted: 25 July 2024
Published: 17 August 2024

DOI
10.25259/CSDM_104_2024

Quick Response Code:



A 30-year-old female office worker with no significant medical history and no immunosuppression presented with a painful lesion on her left sole for 3 months. The lesion was more painful on walking. Clinical examination revealed a tender hyperkeratotic papule [Figure 1]. The pain was more on lateral pressure compared to vertical pressure. Dermoscopy revealed multiple dotted and linear vessels surrounded by yellow-gray structureless areas giving a “frogspawn appearance” with interrupted and distorted dermatoglyphics over the lesion [Figure 2]. Based on the clinical and dermoscopic findings, a diagnosis of plantar wart was confirmed and the patient was advised to apply a combination of salicylic acid (16.7%) and lactic acid (16.7%) paint once daily.

Plantar warts, or verrucae plantaris, are hyperkeratotic papules caused by HPV, predominantly types 1, 2, 4, and 63. These warts often cause significant pain and can impede walking. Dermoscopy significantly enhances the diagnostic accuracy of plantar warts by revealing specific morphological features not visible to the naked eye. The presence of black dots and globules, dotted and linear vessels, frogspawn or falooda seed appearance, and interrupted dermatoglyphics are highly indicative of warts.^[1] These features help differentiate warts from other benign (corns, calluses), and malignant lesions (squamous cell carcinoma). Corns and calluses typically show a central core with intact dermatoglyphics and lack thrombosed capillaries. Squamous cell carcinoma may present with a similar hyperkeratotic appearance but lacks the characteristic black dots and

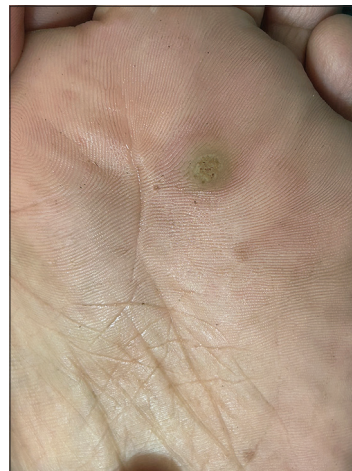

Figure 1: Solitary hyperkeratotic papule of the forefoot.

This is an open-access article distributed under the terms of the Creative Commons Attribution-Non Commercial-Share Alike 4.0 License, which allows others to remix, transform, and build upon the work non-commercially, as long as the author is credited and the new creations are licensed under the identical terms.

©2024 Published by Scientific Scholar on behalf of CosmoDerma

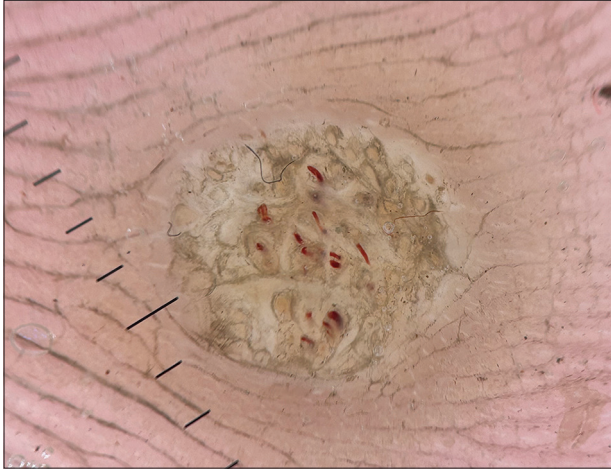


Figure 2: Polarized dermoscopy (Heine DELTAone) showing multiple dotted and linear vessels surrounded by yellow-gray structureless areas giving a “frogspawn appearance” with interrupted and distorted dermatoglyphics over the lesion (×20).

vascular structures of warts.^[1] Dermoscopy can be utilized to evaluate the therapeutic response of trichloroacetic acid in treating warts. Successful treatment is indicated by a uniform white frost and the absence of blood vessels on dermoscopic examination, thus improving treatment assessment and efficacy.^[2]

Ethical approval

The Institutional Review Board approval is not required.

Declaration of patient consent

The authors certify that they have obtained all appropriate patient consent.

Financial support and sponsorship

Nil.

Conflicts of interest

There are no conflicts of interest.

Use of artificial intelligence (AI)-assisted technology for manuscript preparation

The authors confirm that there was no use of artificial intelligence (AI)-assisted technology for assisting in the writing or editing of the manuscript and no images were manipulated using AI.

REFERENCES

1. Al Rudaisat M, Cheng H. Dermoscopy features of cutaneous warts. *Int J Gen Med* 2021;14:9903-12.
2. Rambhia SH, Rambhia KD, Gulati A. Utilizing dermoscopy for trichloroacetic acid (TCA) therapy assessment in genital verruca. *Indian Dermatol Online J* 2024;15:706-7.

How to cite this article: Gaurav V, Agrawal I. Dermoscopy of plantar wart. *CosmoDerma*. 2024;4:107. doi: 10.25259/CSDM_104_2024