

## Letter to the Editor

# A rare case of blistering distal dactylitis in an adult

Shini Choubey<sup>1</sup>, Kiran Vinayak<sup>2</sup>, Farheen Begum<sup>1</sup>

<sup>1</sup>Department of Dermatology, Kalinga Institute of Medical Sciences, Bhubaneswar, Odisha, <sup>2</sup>Department of Dermatology, Priyadarshini Hospital, Payyanur, Kerala, India.



**\*Corresponding author:**  
Shini Choubey,  
Department of Dermatology,  
Kalinga Institute of Medical  
Sciences, Bhubaneswar,  
Odisha, India.

[choubeyshini@gmail.com](mailto:choubeyshini@gmail.com)

Received: 16 July 2024

Accepted: 22 July 2024

Published: 17 August 2024

DOI

10.25259/CSDM\_120\_2024

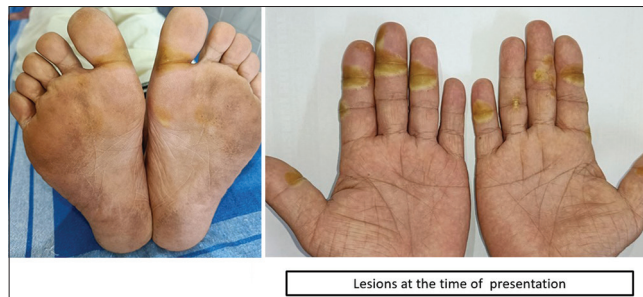Quick Response Code:



Dear Sir,

A 62-year-old male patient presented to the out-patient department with multiple painful lesions and swelling of fingers of bilateral hands and bilateral great toe. On further inquiry, the patient was a known case of pelvic tumor, since 2021. He was operated for the same, two years ago with the tissue section histopathology suggestive of a solitary fibrous tumor. Since then, the patient has been in remission. In December 2023, there was a suspicion of relapse and the patient was started with tyrosinase kinase inhibitor pazopanib with a 400 mg once daily dose. Four weeks after starting pazopanib, he started developing pain and redness on the skin overlying the right proximal interphalangeal joint of all fingers and left great toe which, then, progressed to involve both hands and foot along with the development of pus-filled tense bulla over the course of next one week.

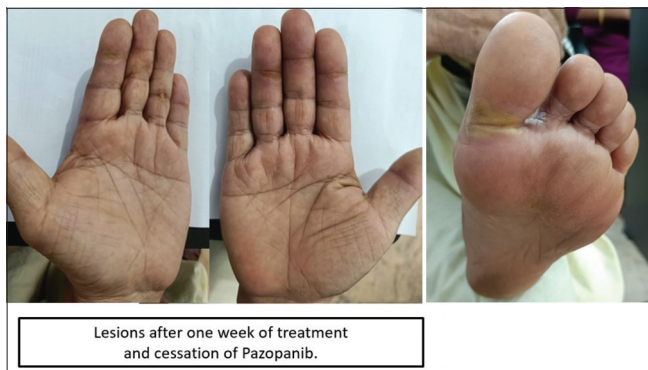
On examination, yellowish-white, desquamating lesions along with tender and tense bullae were present involving the palmar and plantar regions, which were consistent with blistering distal dactylitis (BDD)<sup>[1]</sup> [Figure 1]. The patient was, then, advised for pus culture which showed Methicillin-sensitive *Staphylococcus aureus* growth and the patient was started on oral antibiotics (Cefixime 200 mg twice daily and clobetasol ointment once daily application) for a week and a diagnosis of BDD was made. The patient was advised to discontinue pazopanib. The patient was reviewed after seven days and the skin lesions had resolved [Figure 2].



**Figure 1:** Multiple yellowish-white, tender, and tense bullae present over the palmoplantar region.

This is an open-access article distributed under the terms of the Creative Commons Attribution-Non Commercial-Share Alike 4.0 License, which allows others to remix, transform, and build upon the work non-commercially, as long as the author is credited and the new creations are licensed under the identical terms.

©2024 Published by Scientific Scholar on behalf of CosmoDerma



**Figure 2:** Lesions subsided after 1 week of supportive therapy and cessation of the drug.

Hays and Mullard initially identified BDD in 1972.<sup>[2]</sup> It is an uncommon bacterial infection of the finger's distal phalanx. The causal microbe is generally group A beta-hemolytic *Streptococcus*, with *S. aureus* appearing occasionally. It is more frequent in children and adolescents.<sup>[3]</sup> The BDD is rarely reported in adults, seen in the elderly, diabetic or immunocompromised conditions.<sup>[4]</sup> Methicillin-resistant *S. aureus* is relatively infrequently reported worldwide.<sup>[5]</sup>

In conclusion, it is important to acknowledge this rare entity in adults, which can often be misdiagnosed as to include irritant and allergic contact dermatitis, pompholyx, post-traumatic blisters, blisters caused by thermal injuries, herpetic whitlow, bullous impetigo, erythema multiforme, and epidermolysis bullosa. Even though BDD is never life-threatening, it can have significant detrimental effects on quality of life and cause severe discomfort and functional impairment, particularly in older people. The treatment includes topical and/or systemic antibiotics that are used in addition to incision and drainage if required. No treatment failures have been documented.<sup>[6]</sup>

### Ethical approval

The Institutional Review Board approval is not required.

### Declaration of patient consent

The authors certify that they have obtained all appropriate patient consent.

### Financial support and sponsorship

Nil.

### Conflicts of interest

There are no conflicts of interest.

### Use of artificial intelligence (AI)-assisted technology for manuscript preparation

The authors confirm that there was no use of artificial intelligence (AI)-assisted technology for assisting in the writing or editing of the manuscript and no images were manipulated using AI.

### REFERENCES

1. Veraldi S, Schianchi R, Nazzaro G, Cambiaghi S. Seven cases of blistering dactylitis. *Acta Derm Venereol* 2020;100:5757.
2. Hays GC, Mullard JE. Can nasal bacterial flora be predicted from clinical findings? *Pediatrics* 1972;49:596-9.
3. Kollipara R, Downing C, Lee M, Guidry J, Robare-Stout S, Tyring S. Blistering distal dactylitis in an adult. *J Am Acad Dermatol* 2015;19:397-9.
4. Hinkamp CA, Shah NH, Holland N, Wright A. Recurrent blistering distal dactylitis due to *Staphylococcus aureus* in an immunocompetent elderly woman. *BMJ Case Rep* 2018;2018:bcr2017222772.
5. Fretzayas A, Moustaki M, Tsagris V, Brozou T, Nicolaidou P. MRSA blistering distal dactylitis and review of reported cases. *Pediatr Dermatol* 2011;28:433-5.
6. Scheinfeld NS. Is blistering distal dactylitis a variant of bullous impetigo? *Clin Exp Dermatol* 2007;32:314-6.

**How to cite this article:** Choubey S, Vinayak K, Begum F. A rare case of blistering distal dactylitis in an adult. *CosmoDerma*. 2024;4:105. doi: 10.25259/CSDM\_120\_2024