

Innovations

Surgical pearl: A simple and safe innovative technique to handle the razor blade with fingers

Muhammed Mukhtar¹, Maria Mukhtar¹

¹Department of Dermatology, Mukhtar Skin Centre, Katihar, Bihar, India.



***Corresponding author:**
Muhammed Mukhtar,
Department of Dermatology,
Mukhtar Skin Centre, KMCH
Road, Katihar, Bihar, India.
drmmukhtar20@gmail.com

Received : 17 February 2023
Accepted : 20 March 2023
Published : 29 March 2023

DOI
10.25259/CSDM_48_2023

Videos available online at
https://doi.org/10.25259/CSDM_48_2023

Quick Response Code:



PROBLEM

A razor blade is a cost-effective, readily available, and sharp device for shaving surgery in dermatology.^[1] However, its handling with the finger is a challenging job. The blade is handled generally with artery forceps, a needle holder, and a dermatome knife during shaving surgery and Thiersch's graft harvesting.^[2,3] During these surgeries, better control of the blade and proper alignment with the skin are required. The primitive way of manipulating a blade with our fingers is dangerous, but it gives excellent control and alignment with the skin surface, and no sterile handle is required. To prevent finger damage, a new approach is employed to cover the blade's handling edge with adhesive tape, which is commonly accessible, aseptic, disposable, and inexpensive.

SOLUTION

To combat the problems of finger safety and alignment with the skin, one edge of the blade is wrapped with adhesive micropore or leucoplast tape (or Surgical Adhesive Elastoplast) [Figure 1]. Following this, the blade is bent or folded by 30–45° at its connecting part. During the procedure,

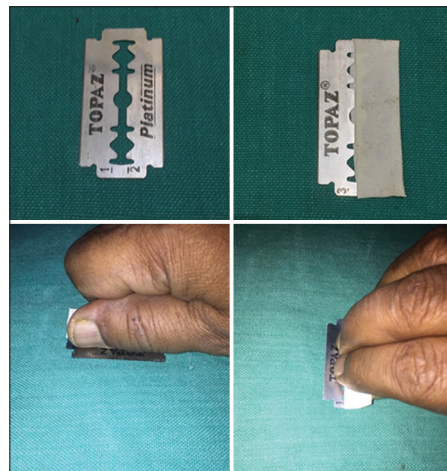


Figure 1: The full blade edge to be held with a finger is covered with adhesive tape.

This is an open-access article distributed under the terms of the Creative Commons Attribution-Non Commercial-Share Alike 4.0 License, which allows others to remix, transform, and build upon the work non-commercially, as long as the author is credited and the new creations are licensed under the identical terms.

©2023 Published by Scientific Scholar on behalf of CosmoDerma

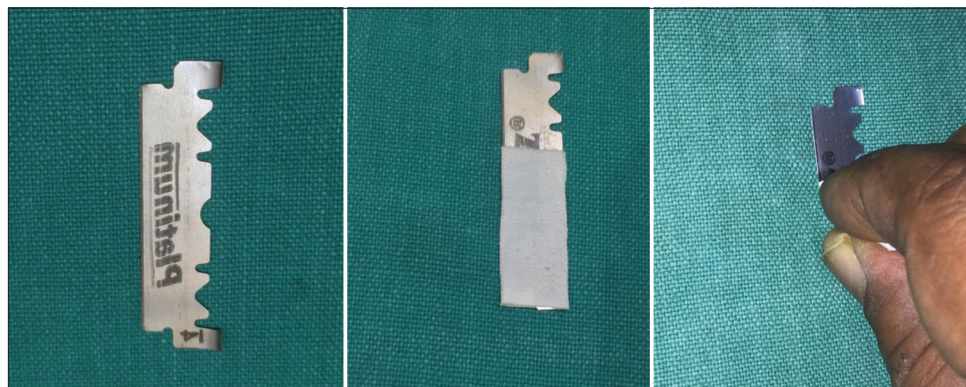



Figure 2: The wrapped half edge of the halved blade.



Video 1: The wrapped-edge blade is being handled with the finger while the cutting edge is to be used for shaving surgery.



Video 2: The wrapped half edge of a halved blade can be used for shaving small skin lesions.

the wrapped part is handled with fingers, while the other part is used for the shaving surgery [Video 1]. During its use, there is no apprehension of finger injury, and the cutting edge of the blade has proper alignment with the skin surface and very good control on the blade and its movement due to fingers. Thus, this customization of the blade can be a good option for handling the blade, better shaving surgery, and ultra-thin Thiersch's graft harvesting. For a tiny cutting edge, the blade is divided lengthwise at the connecting component, and then half of its cutting edge is covered in tape for finger safety [Figure 2 and Video 2].

Declaration of patient consent

Patient's consent not required as patients identity is not disclosed or compromised.

Financial support and sponsorship

Nil.

Conflicts of interest

There are no conflicts of interest.

REFERENCES

1. Awadalla F, Hexsel C, Goldberg LH. The sharpness of blades used in dermatologic surgery. *Dermatol Surg* 2016;42:105-7.
2. Mukhtar M, Mukhtar N. A modified razor blade for better finger grip during shave surgery. *CosmoDerma* 2023;3:5.
3. Mukhtar M. A halved angulated small razor blade with double advantage for safe shaving surgery. *CosmoDerma* 2022;2:108.

How to cite this article: Mukhtar M, Mukhtar M. Surgical pearl: A simple and safe innovative technique to handle the razor blade with fingers. *CosmoDerma* 2023;3:59.