

Visual Treats in Dermatology

Indurated plaque on the nape of the neck

Kanmani Indra Couppoussamy¹, Suruthi Purushothaman¹

¹Department of Dermatology, JIPMER, Puducherry, India.



***Corresponding author:**

Kanmani Indra Couppoussamy,
 Department of Dermatology,
 JIPMER, Puducherry, India.

kanzfelicz@gmail.com

Received : 01 December 2022

Accepted : 20 December 2022

Published : 06 January 2023

DOI

10.25259/CSDM_157_2022

Quick Response Code:



A 40-year-old male presented with asymptomatic raised lesion over the nape of the neck for 1 year. On examination, skin colored indurated plaque of size 3 × 4 cm is present over the nape of the neck with multiple tiny papules along the margin of the plaque with scarring alopecia [Figure 1]. Based on the history and clinical examination, a diagnosis of acne keloidalis nuchae was made. The lesion responded to intralesional triamcinolone injection 10 mg/mL over three sessions given monthly. Acne keloidalis nuchae is a type of chronic folliculitis characterized by papules and pustules in the nuchal and occipital region. Clinically, it can resemble keloid in the later stages, by histologically, it shows perifollicular inflammation with lymphocytes and plasma cells at the level of isthmus and lower infundibulum. It lacks the histological features of keloid.

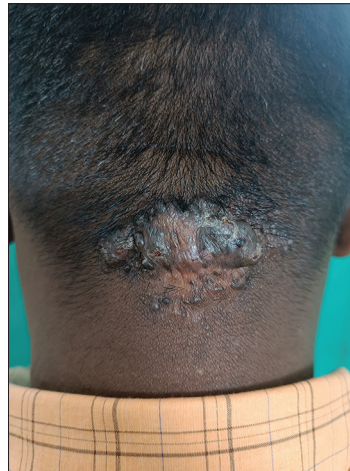


Figure 1: Skin coloured indurated plaque of size 3 × 4 cm in the nape of the neck with multiple papules along its margin and scarring alopecia.

This is an open-access article distributed under the terms of the Creative Commons Attribution-Non Commercial-Share Alike 4.0 License, which allows others to remix, transform, and build upon the work non-commercially, as long as the author is credited and the new creations are licensed under the identical terms.

©2023 Published by Scientific Scholar on behalf of CosmoDerma

The treatment options include topical steroids, intralesional steroid, oral tetracyclines, and surgical excision.^[1]

Declaration of patient consent

The authors certify that they have obtained all appropriate patient consent.

Financial support and sponsorship

Nil.

Conflicts of interest

There are no conflicts of interest.

REFERENCE

1. Ogunbiyi A. Acne keloidalis nuchae: Prevalence, impact, and management challenges. Clin Cosmet Investig Dermatol 2016;9:483-9.

How to cite this article: Couppoussamy KI, Purushothaman S. Indurated plaque on the nape of the neck. CosmoDerma 2023;3:6.