

Visual Treats in Dermatology

Pediculosis pubis under the lens

Arunachalam Narayanan

Department of Dermatology and STD, Jawaharlal Institute of Postgraduate Medical Education and Research, Puducherry, India.



***Corresponding author:**

Arunachalam Narayanan,
 Department of Dermatology
 and STD, Jawaharlal Institute
 of Postgraduate Medical
 Education and Research,
 Puducherry, India.

narayanan359@gmail.com

Received : 08 December 2022

Accepted : 15 December 2022

Published : 05 January 2023

DOI

10.25259/CSDM_160_2022

Videos available online at

[https://doi.org/10.25259/
 CSDM_160_2022](https://doi.org/10.25259/CSDM_160_2022)

Quick Response Code:



A 30-year-old man presented to our clinic with history of multiple, small, and black insects crawling out of his umbilicus. On examination, his umbilicus was clean. However, we found numerous crab lice attached to the base of his pubic hair. We did not observe any macula ceruleae. Microscopy ($\times 10$) demonstrated the presence of crab lice with three pairs of short and jointed legs [Video 1 and Figure 1]. We made a diagnosis of pediculosis pubis based on the clinical history and examination findings. We prescribed permethrin 1% cream application over the affected areas followed by washing it 10 min later. The treatment was repeated after 10 days followed by complete resolution.^[1] Pediculosis pubis may also involve other hair-bearing areas such as axillae, scalp, eyebrows, eyelashes, beard, and areolar hair. The louse is characterized by

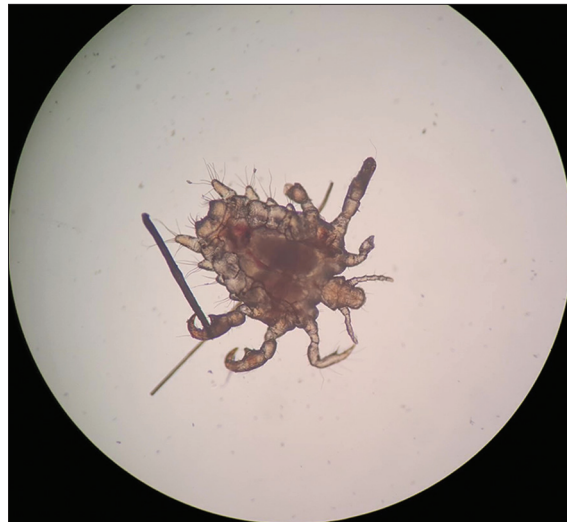


Figure 1: Crab lice with three pairs of short and jointed legs.

This is an open-access article distributed under the terms of the Creative Commons Attribution-Non Commercial-Share Alike 4.0 License, which allows others to remix, transform, and build upon the work non-commercially, as long as the author is credited and the new creations are licensed under the identical terms.

©2023 Published by Scientific Scholar on behalf of CosmoDerma



Video 1: Crab lice with three pairs of short and jointed legs.

a short, wide body with clawed legs except for the first pair, which is shortened and vestigial.

Declaration of patient consent

Patient's consent not required as patients identity is not disclosed or compromised.

Financial support and sponsorship

Nil.

Conflicts of interest

There are no conflicts of interest.

REFERENCE

1. Patel PU, Tan A, Levell NJ. A clinical review and history of pubic lice. Clin Exp Dermatol 2021;46:1181-8.

How to cite this article: Narayanan A. Pediculosis pubis under the lens. CosmoDerma 2023;3:1.