

Innovations

Ventral penile taping: A simple technique for assistant-free scrotal surgery

Surajit Gorai¹

¹Department of Dermatology, Apollo Multispeciality Hospital, Kolkata, West Bengal, India.



*Corresponding author:

Dr. Surajit Gorai,
Department of Dermatology,
Apollo Multispeciality Hospital,
Kolkata, West Bengal, India.

drsurajit@drgorai.com

Received: 15 November 2024
Accepted: 29 November 2024
Published: 11 January 2025

DOI
10.25259/CSDM_194_2024

Quick Response Code:



PROBLEM

Performing scrotal surgeries, such as the excision of idiopathic scrotal calcinosis with radiofrequency, often poses a practical challenge: Positioning and stabilizing the penis [Figure 1]. This difficulty is compounded in dermatology procedure rooms or minor operation theaters, where dermatosurgeons frequently operate without an assistant. Conventionally, an assistant is required to hold the penis away from the surgical field, but the lack of availability can complicate procedures, prolong operative time, and affect precision.

SOLUTION

Ventral penile taping (VPT) is a simple, innovative technique to address this issue. After placing the patient in a supine position, a strip of micropore tape is applied to the ventral surface of the penis and secured to the lower abdomen [Figures 2 and 3]. This maneuver holds the penis away

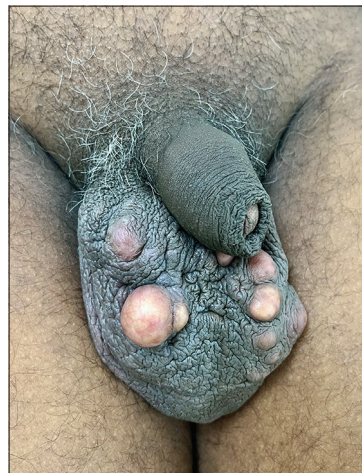


Figure 1: Image showing the penoscrotal area with idiopathic scrotal calcinosis, illustrating how the penis may interfere with scrotal procedures.

This is an open-access article distributed under the terms of the Creative Commons Attribution-Non Commercial-Share Alike 4.0 License, which allows others to remix, transform, and build upon the work non-commercially, as long as the author is credited and the new creations are licensed under the identical terms.

©2025 Published by Scientific Scholar on behalf of CosmoDerma

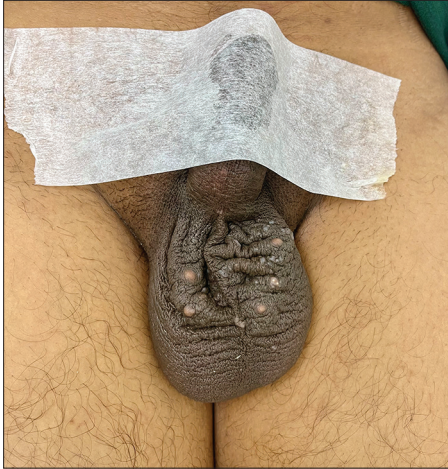

Figure 2: Image of the penoscrotal area with ventral penile taping (VPT) in position, demonstrating the correct technique for performing VPT.

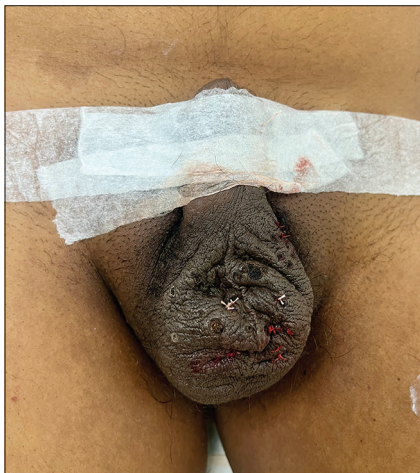

Figure 3: Image of the penoscrotal area with ventral penile taping in position, illustrating the effective execution of the procedure for idiopathic scrotal calcinosis.

from the operative field, ensuring unobstructed access to the scrotum. VPT eliminates the need for an assistant while maintaining a sterile and stable surgical environment.

This approach significantly enhances procedural efficiency, allowing the surgeon to work independently without compromising safety or precision. Moreover, it reduces operative time and ensures optimal patient positioning throughout the procedure. This method is reliable and reproducible. The simplicity and effectiveness of VPT make it an indispensable tool for dermatologists performing scrotal surgeries in minor OT settings or procedure rooms. With minimal cost and effort, this technique has the potential to streamline scrotal procedures and support dermatosurgeons in delivering high-quality care independently. A similar technique can be applied for body folds or operation over the ear lobe/post auricular area as in the ear lobe keloid.

VPT offers a practical, assistant-free solution for scrotal surgeries, making it an essential addition to the dermatosurgeon's repertoire.

Ethical approval

Institutional Review Board approval is not required.

Declaration of patient consent

The author certifies that he has obtained all appropriate patient consent.

Financial support and sponsorship

Nil.

Conflicts of interest

There are no conflicts of interest.

Use of artificial intelligence (AI)-assisted technology for manuscript preparation

The authors confirm that there was no use of artificial intelligence (AI)-assisted technology for assisting in the writing or editing of the manuscript and no images were manipulated using AI.

How to cite this article: Gorai S. Ventral penile taping: A simple technique for assistant-free scrotal surgery. *CosmoDerma*. 2025;5:13. doi: 10.25259/CSDM_194_2024