

Visual Treats in Dermatology

Verrucous and crusted plaques of rhinosporidiosis

C. K. Sriram¹, M. Sri Krishna Priya¹

¹Department of Dermatovenereology, Velammal Medical College and Research Institute, Madurai, Tamil Nadu, India.



***Corresponding author:**

C. K. Sriram,
Department of
Dermatovenereology, Velammal
Medical College and Research
Institute, Madurai, Tamil Nadu,
India.

cksriram49@gmail.com

Received : 28 January 2023

Accepted : 07 March 2023

Published : 20 March 2023

DOI

10.25259/CSDM_30_2023

Quick Response Code:



A 70-year-old male presented with multiple raised lesions over the left side of the back for the past 2 years. Initially, the lesions were small to start with and gradually increased in size and number and attained the present size. There were no lesions elsewhere in the body including oral, nasal, and genital mucosa other than this site. He could not remember any history of trivial trauma. He had a habit of bathing in a common pool in his village. On dermatological examination, there were multiple verrucous and fragile exophytic growths of varying sizes over the left side of the back region unilaterally [Figure 1]. There were some skin-colored papules seen interspersed among them. These growths were crushed and examined under 10% potassium hydroxide [Figure 2]. It revealed multiple double-walled sporangia filled with sporangiospores suggestive of cutaneous rhinosporidiosis. Serology for human immunodeficiency virus 1 and 2 was done and turned non-reactive. Cutaneous rhinosporidiosis can present like

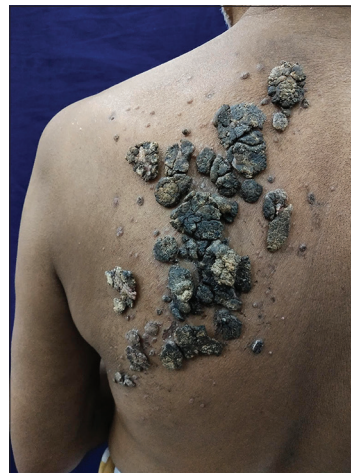

Figure 1: Multiple pigmented verrucous lesions over back.

This is an open-access article distributed under the terms of the Creative Commons Attribution-Non Commercial-Share Alike 4.0 License, which allows others to remix, transform, and build upon the work non-commercially, as long as the author is credited and the new creations are licensed under the identical terms.

©2023 Published by Scientific Scholar on behalf of CosmoDerma

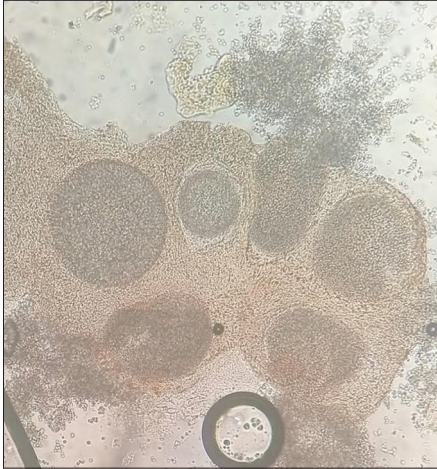


Figure 2: Multiple double-walled sporangia with sporangiospores seen under light microscopy (10 × 10 magnification).

verruca vulgaris, tuberculosis verrucosa cutis, granuloma pyogenicum, venereal warts, and donovanosis.^[1] This case was interesting due to the extensive distribution of

cutaneous rhinosporidiosis in an immunocompetent male without any mucosal involvement.

Declaration of patient consent

Patient's consent not required as patient's identity is not disclosed or compromised.

Financial support and sponsorship

Nil.

Conflicts of interest

There are no conflicts of interest.

REFERENCE

1. Yesudian P. Cutaneous rhinosporidiosis mimicking verruca vulgaris. *Int J Dermatol* 1988;27:47-9.

How to cite this article: Sriram CK, Krishna Priya MS. Verrucous and crusted plaques of rhinosporidiosis. *CosmoDerma* 2023;3:51.