

## Innovations

# A modified razor blade for better finger grip during shave surgery

Muhammed Mukhtar<sup>1</sup>, Nadia Mukhtar<sup>1</sup>

<sup>1</sup>Department of Dermatology, Mukhtar Skin Centre, Katihar, Bihar, India.



**\*Corresponding author:**

Muhammed Mukhtar,  
Department of Dermatology,  
Mukhtar Skin Centre, Katihar,  
Bihar, India.

drmmukhtar20@gmail.com

Received : 19 November 2022

Accepted : 28 December 2022

Published : 06 January 2023

**DOI**

10.25259/CSDM\_147\_2022

**Videos available online at**

[https://doi.org/10.25259/CSDM\\_147\\_2022](https://doi.org/10.25259/CSDM_147_2022)

**Quick Response Code:**




## PROBLEM

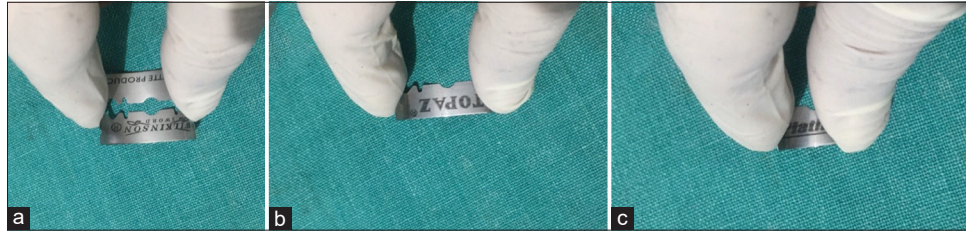A razor blade is one of the sharpest instruments used in shaving surgery.<sup>[1]</sup> However, it is difficult to handle due to its flexibility and poor finger grip, and there is a risk of finger injury.<sup>[2,3]</sup> Various modifications have been documented to increase the finger grip as of a DermaBlade, but all of these are equally cumbersome and a little expensive.

## SOLUTION

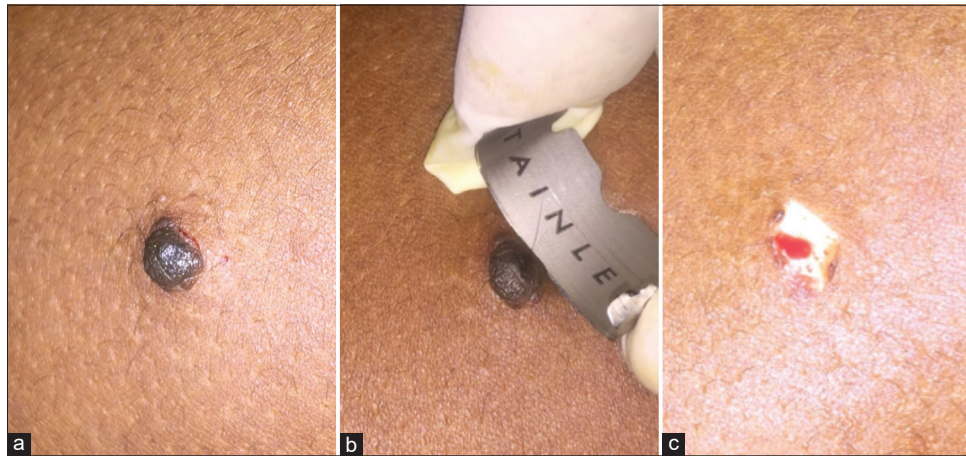
We took a double edge razor blade (Topaz, 7 o'clock, Wilkinson Sword, 43 mm × 22 mm) and a needle holder, and both sides of the blade were bent by the needle holder by 30–45° to improve the finger grip and facilitate easy handling. These blades can be used for shaving larger lesions. To get a short cutting edge, the blade is divided lengthwise, and the sides are clipped and bent in the same way. These blades are used for shaving small lesions. Thus, these customized and modified razor blades can be a good alternative for shaving surgery of benign skin lesions [Figure 1a-c]. The blades can be held in a better way [Figure 2a-c]. With this blade, benign skin lesions can be cut or shaved, saucerized, and scooped easily due to its sharpness in comparison to commonly available surgical blades. The residual lesions, if any, on the margin, can be shaved with the blade or snipped with iris scissors [Figure 3a-c and Video 1]. The disadvantage of this device is that



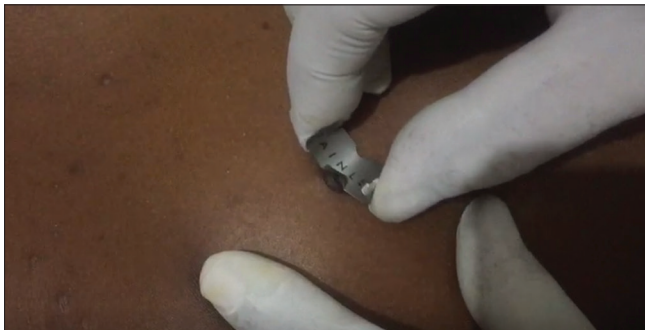**Figure 1:** (a-c) The sides of the razor blade (full and half) are bent with the needle holder for better finger grip.



**Figure 2:** (a-c) The customized razor blades are held with fingers.



**Figure 3:** (a-c) A melanocytic nevus is shaved with the blade.



**Video 1:** The melanocytic nevus is being shaved with the blade.

we can get a cut on our finger during its procurement. The lateral cutting edge of this blade can be trimmed to prevent finger injuries.

#### **Declaration of patient consent**

Patient's consent not required as patients identity is not disclosed or compromised.

#### **Financial support and sponsorship**

Nil.

#### **Conflicts of interest**

There are no conflicts of interest.

#### **REFERENCES**

1. Awadalla F, Hexsel C, Goldberg LH. The sharpness of blades used in dermatologic surgery. *Dermatol Surg* 2016;42:105-7.
2. Mushtaq S. Shave biopsy instrument: An ergonomic modification of razor blade. *J Cutan Aesthet Surg* 2020;13:255-6.
3. Yang SH, Qi J, Esandrio J, Leung S, Taube JM, Garza LA, *et al*. Efficacy and tolerability of a novel biopsy device for removing benign epidermal skin lesions. *Dermatol Surg* 2015;41:1264-73.

**How to cite this article:** Mukhtar M, Mukhtar N. A modified razor blade for better finger grip during shave surgery. *CosmoDerma* 2023;3:5.