

Innovations

Surgical pearl: Topical thermo-sclero-cautery for shaved palmoplantar viral wart

Muhammed Mukhtar¹, Nadia Mukhtar¹

¹Department of Dermatology, Mukhtar Skin Centre, Katihar Medical College, Katihar, Bihar, India.



***Corresponding author:**
Muhammed Mukhtar,
Department of Dermatology,
Mukhtar Skin Centre, Katihar
Medical College, Katihar, Bihar,
India.

drmmukhtar20@gmail.com

Received : 20 November 2022

Accepted : 23 December 2022

Published : 06 January 2023

DOI

10.25259/CSDM_149_2022

Quick Response Code:



PROBLEM

Topical treatment is often ineffective in treating hyperkeratotic palmoplantar viral warts, and it offers a therapeutic challenge for dermatologists. The feeding capillaries of the wart are its major source of blood supply and survival. The thrombosis and sclerosis of these capillaries are the basis of the treating warts. These feeding capillaries can be topically cauterized and sclerosed using chemical and sclerosing agents.^[1,2] The author has suggested a simple method for treating viral warts based on these therapeutic concepts.

SOLUTION

To improve the effectiveness of the topical chemical cautery, the exophytic surface of the palmoplantar wart is shaved with a blade without local anaesthesia to expose the feeding vessels of the warts. Following that, hemostasis is achieved by applying pressure with a cotton ball soaked in saturated hypertonic saline, which has vascular sclerosis, thrombosis, intracellular hypertonicity such as cryogenes and antiseptic properties). Then, 100% of trichloroacetic acid (TCA) is applied topically for cauterizing the exposed part of the lesions after shaving. After that, the patient is told to use 2–3 times the warm, saturated hypertonic saline at home for 4–6 weeks to take care of the remnant lesions of warts using thermosclerotherapy. The patient was seen once a week for the following 6 weeks. The warts disappeared after 3–4 weeks [Figure 1a-c]. There

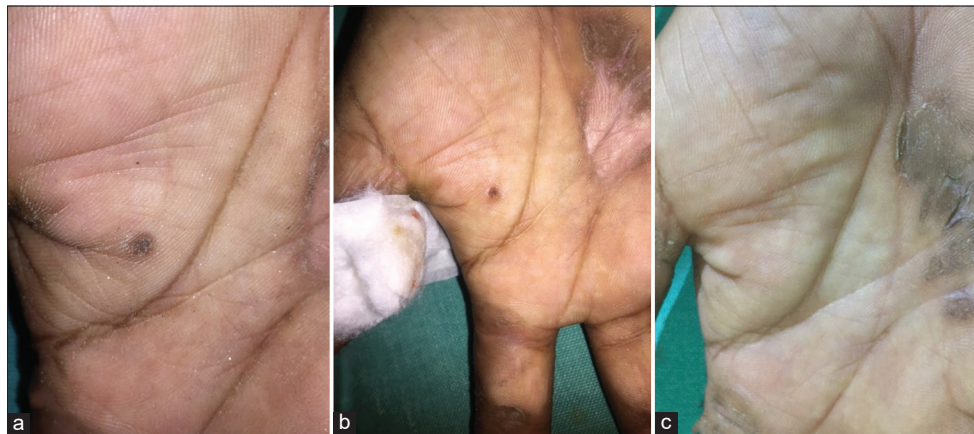


Figure 1: (a-c) A palmar wart is treated with shaving and thermo-sclero-cautery therapy.

This is an open-access article distributed under the terms of the Creative Commons Attribution-Non Commercial-Share Alike 4.0 License, which allows others to remix, transform, and build upon the work non-commercially, as long as the author is credited and the new creations are licensed under the identical terms.

©2023 Published by Scientific Scholar on behalf of CosmoDerma

have been no adverse effects or recurrences of the lesions at the treated site. Thus, thermo-sclero-cautery therapy using warm, saturated, and hypertonic saline, TCA with shaving can be an effective and simple treatment option for resistant and chronic palmoplantar viral warts.

Declaration of patient consent

Patient's consent not required as patient's identity is not disclosed or compromised.

Financial support and sponsorship

Nil.

Conflicts of interest

There are no conflicts of interest.

REFERENCES

1. Mu MH, Wang YN, Huang Y, Niu XL, Chen HD, Gao XH, *et al.* Local hyperthermia cleared multifarious viral warts in a patient with Cushing's syndrome. *Dermatol Ther* 2019;32:e12815.
2. Mukhtar M. The role of hypertonic saline in the treatment of labial mucoceles. *Cosmet Dermatol Cedar Knolls* 2003;16:48-55.

How to cite this article: Mukhtar M, Mukhtar N. Surgical pearl: Topical thermo-sclero-cautery for shaved palmoplantar viral wart. *CosmoDerma* 2023;3:9.