

## Innovations

# A simple technique of uncurling and transfer of pedunculated blister graft using slide and syringe barrel

Muhammed Mukhtar<sup>1</sup>, Nadia Mukhtar<sup>1</sup>

<sup>1</sup>Department of Dermatology, Mukhtar Skin Centre, Katihar, Bihar, India.



**\*Corresponding author:**  
Muhammed Mukhtar,  
Department of Dermatology,  
Mukhtar Skin Centre,  
Katihar - 854105, Bihar, India.  
drmmukhtar20@gmail.com

Received : 06 November 2022  
Accepted : 17 November 2022  
Published : 28 November 2022

DOI  
10.25259/CSDM\_139\_2022

Videos available online at  
[https://doi.org/10.25259/  
CSDM\\_139\\_2022](https://doi.org/10.25259/CSDM_139_2022)

Quick Response Code:

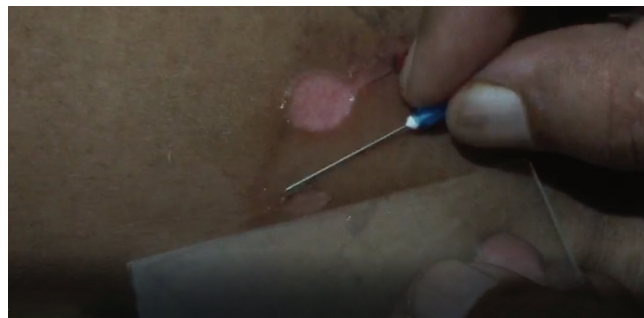

## PROBLEM

Suction blister epidermal grafting is a common surgical technique for fast a esthetic repigmentation of small-sized stable vitiligo. However, transporting the uncurled graft from the donor site to the recipient site is one of the most challenging aspects of this technique. Glass slide and syringe barrel are common platforms for graft transfer.<sup>[1,2]</sup> However, the existing graft transfer technique involves harvesting from the site, transferring it on the transporting device, and then uncurling the harvested graft on the transport device, which increases time and confusion in uncurling and sometimes in identifying the surface if by chance the graft turns upside down during this procedure. This article describes an innovative transfer of the graft over the transporting platform.

## SOLUTION

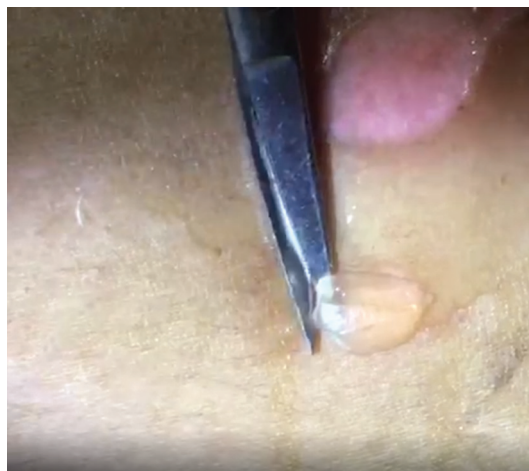To solve the difficulties of uncurling and surface identification, the majority of the blister margin is cut with iris scissors, leaving a small part of the blister margin connected to the skin as a pedicle. Then, the graft is spread out over the suction site to uncurl and anti-wrinkle from the dorsal and ventral surface side [Videos 1 and 2]. Following that, the graft is transferred to the slide and spread it out from the ventral/dermal surface. Finally, the blister graft's pedicle is severed [Figure 1a-c]. This graft pedicle provides stability, simplicity, and convenience in spreading out the blister graft from both sides before harvestation of the graft. A syringe barrel can be used in the same way in place of the slide [Figure 2a-c].



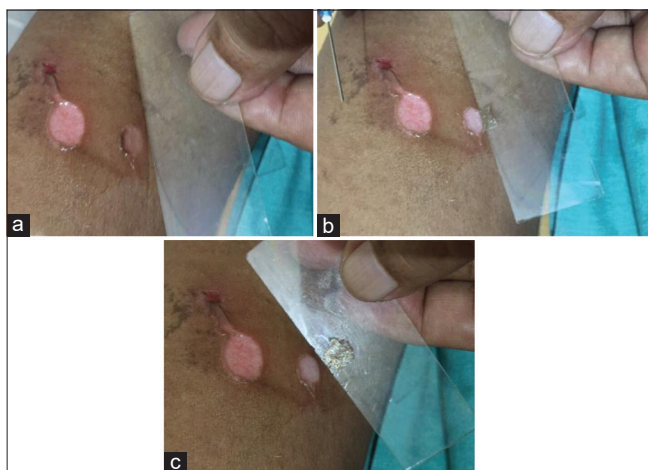
**Video 1:** The pedunculated blister graft is uncurled and anti-wrinkled from dorsal surface of the graft.

This is an open-access article distributed under the terms of the Creative Commons Attribution-Non Commercial-Share Alike 4.0 License, which allows others to remix, transform, and build upon the work non-commercially, as long as the author is credited and the new creations are licensed under the identical terms.

©2022 Published by Scientific Scholar on behalf of CosmoDerma



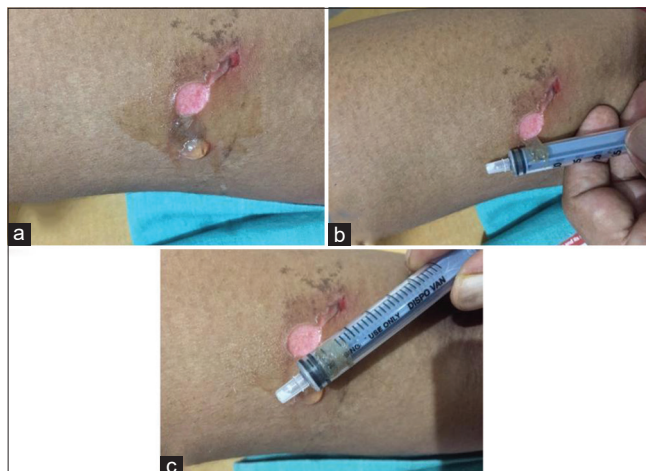
**Video 2:** The pedunculated blister graft is uncurled and anti-wrinkled from ventral surface of the graft.



**Figure 1:** (a-c) The harvested blister graft with pedicle is spread out at the blister site (a) and then it is transferred, uncurled over the glass slide (b) and harvested (c).

The benefits of this strategy are as follows:

1. It is a quick, simple, and reliable procedure
2. The graft is stabilized due to its pedicle and simple to uncurl, anti-wrinkle from both sides before its complete harvestation
3. There is no uncertainty concerning the graft's surface.



**Figure 2:** (a-c) The harvested blister graft with pedicle is spread out at the blister site (a) then graft is transferred and spread out on disposable syringe barrel (b) and harvested (c).

#### Declaration of patient consent

Patient's consent not required as patients identity is not disclosed or compromised.

#### Financial support and sponsorship

Nil.

#### Conflicts of interest

There are no conflicts of interest.

#### REFERENCES

1. Mukhtar M, Singh S, Shukla VK, Pandey SS. Surgical pearl: Suction syringe for epidermal grafting. *J Am Acad Dermatol* 1997;37:638-9.
2. Singh BS, Agrawal I, Kar BR. Use of disposable syringe for transfer of graft in suction blister grafting. *J Am Acad Dermatol* 2022;86:e43-4.

**How to cite this article:** Mukhtar M, Mukhtar N. A simple technique of uncurling and transfer of pedunculated blister graft using slide and syringe barrel. *CosmoDerma* 2022;2:123.