

Letter to the Editor

## Dermoscopy: A reliable guide in the diagnosis of lichen planus-like keratosis in an appropriate clinical setting

Biswanath Behera<sup>1</sup>, Rashmi Kumari<sup>2</sup>, Devinder Mohan Thappa<sup>3</sup>, Debasis Gochhait<sup>4</sup>

<sup>1</sup>Department of Dermatology, AIIMS, Bhubaneswar, Odisha, Departments of <sup>2</sup>Dermatology, <sup>3</sup>Dermatology and STD, <sup>4</sup>Pathology, Jawaharlal Institute of Postgraduate Medical Education and Research, Puducherry, India.



**\*Corresponding author:**

Rashmi Kumari,  
Department of Dermatology,  
Jawaharlal Institute of  
Postgraduate Medical  
Education and Research,  
Puducherry, India.

[rashmi.sreerag@gmail.com](mailto:rashmi.sreerag@gmail.com)

Received : 25 August 2022  
Accepted : 03 September 2022  
Published : 15 September 2022

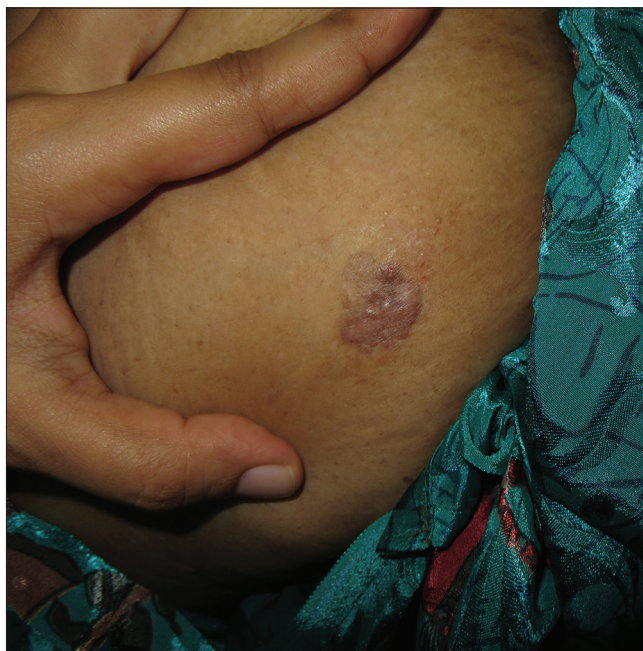DOI  
10.25259/CSDM\_93\_2022

Quick Response Code:



Dear Sir,

A 54-year-old female with skin phototype IV presented with 6 months history of a variable itchy skin lesion over the lower abdomen. Cutaneous examination revealed solitary well-to-ill-defined skin-colored to reddish-brown plaque (2 cm × 2 cm) with an uneven surface and surface erosion [Figure 1]. Differential diagnoses of sarcoidosis, lupus vulgaris, plaque-type granuloma annulare, and Bowen's disease were considered. Dermoscopy under non-polarized contact mode showed multiple tiny erosions, homogenous white to gray areas, brown dots (circumscribed, small, and round), blue-gray fine, and coarse peppering (non-circumscribed and not round), and focal clustered glomerular vessels [Figure 2]. After dermoscopic examination, a differential diagnosis of lichen planus-like keratosis (LPLK) was added. Histology revealed orthohyperkeratosis, focal mounds of parakeratosis, hypergranulosis,



**Figure 1:** Solitary well-to-ill-defined skin-colored to reddish-brown plaque.

This is an open-access article distributed under the terms of the Creative Commons Attribution-Non Commercial-Share Alike 4.0 License, which allows others to remix, transform, and build upon the work non-commercially, as long as the author is credited and the new creations are licensed under the identical terms.

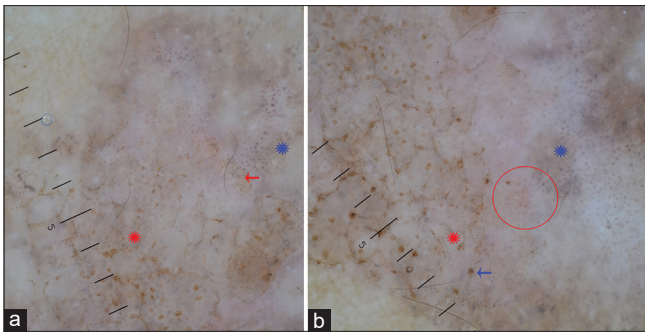
©2022 Published by Scientific Scholar on behalf of CosmoDerma

atrophic epidermis, basal vacuolar degeneration, cytoid bodies, melanophages, and upper perivascular moderate lymphohistiocytic infiltration [Figure 3a and b]. The diagnosis of LPLK was made.

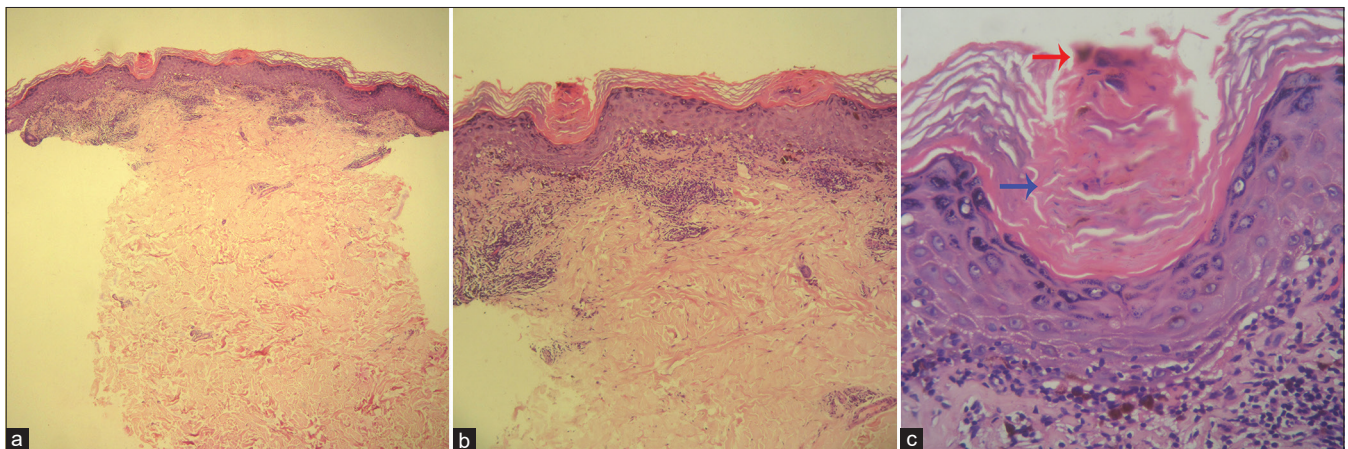
LPLK, otherwise called benign lichenoid keratosis, is a relatively common benign dermatosis. The original description, in 1966, is because of its histopathological resemblance to LP but without any clinical similarity. It usually skips the diagnosis and is mistaken for another benign and malignant cutaneous neoplasm. In a recent review of 1366 cases of LPLK, only in 5.2% of cases, a differential diagnosis of LPLK was considered, and none of them had a clinical impression of lichen planus. The most common clinical impression was basal cell carcinoma and squamous cell carcinoma. In 8% of the cases, it mimicked a melanocytic lesion, including atypical nevus and melanoma. The majority of the lesions

belong to the classic variant (non-pigmented), and other rare variants include atrophic (pigmented), bullous, and mycosis fungoides-like.<sup>[1,2]</sup> In contrast to previously reported female preponderance, a recent study found an almost equal prevalence between males and females. The chest is the most commonly affected region, followed by the back and forearm, while the head and neck are not affected. In Asians, the head and neck were the frequent sites of involvement, and the trunk was rarely affected.<sup>[1]</sup> A recent study from the West Asian population reported a higher frequency of pigmented LPLK and a lower incidence in females.<sup>[3]</sup> A relationship of LPLK with solar lentigo (SL) and reticulated seborrheic keratosis (SK) has been demonstrated.<sup>[4]</sup> The differential diagnoses of LPLK, both for pigmented and non-pigmented variants, can be different in dark skin phototypes than in fair-skinned individuals. In contrast to a common presentation, an erythematous papule or plaque, a skin-colored to reddish-brown plaque, was noticed in the index case, leading us to consider mainly granulomatous dermatoses.

The role of dermoscopic examination in diagnosing various cutaneous dermatoses is expanding due to its direct dermoscopic-pathologic correlating properties. Thus, despite the variable clinical morphology, a dermoscopic examination can reflect the histopathological features of the dermatosis. A recent study showed the presence of orange color and scale to be predictive of LPLK. In addition, the presence of coarse peppering and only peppering was the dermoscopic feature for pigmented LPLK.<sup>[5]</sup> In the index case, a plaque of non-pigmented LPLK, the observed dermoscopic pattern helped in ruling out other differentials and pointed to the diagnosis of LPLK due to the presence of fine and coarse brown and blue-gray peppering. The blue-gray peppering corresponds to the dermal melanophages and pigment incontinence and brown dots and peppering to increase



**Figure 2:** (a) Dermoscopy (HEINE DELTA20®, Germany, 10×) under non-polarized contact mode shows multiple erosions, homogenous white to gray areas, brown dots (red asterisk), and blue-gray fine (red arrow), and coarse peppering (blue asterisk). (b) Dermoscopy shows erosion (blue arrow), brown dots (red asterisk), blue-gray coarse peppering (blue asterisk), and focal clustered glomerular vessels (circle).



**Figure 3:** (a) Histology shows orthohyperkeratosis, focal mounds of parakeratosis, hypergranulosis, loss of rete ridges, basal vacuolar degeneration, cytoid bodies, melanophages, and upper perivascular moderate lymphohistiocytic infiltration (H&E, ×50). (b) Prominent basal vacuolar degeneration and cytoid bodies (H&E, ×100). (c) Mounds of parakeratosis (blue arrow) and melanin (red arrow, H&E, ×400).

epidermal pigmentation or melanin in the stratum corneum. In contrast to an orange color, in the index case, we observed homogenous areas of varying color, possibly due to the dark skin color of the patient. The dermoscopic diagnosis of LPLK is relatively easy when associated with an SL or SK, which reflects the intermediate regressing stage.<sup>[6]</sup> However, in the absence of clinical or dermoscopic features of SL or SK, the diagnosis of LPLK can be challenging, in which case, a coarse peppering with or without fine peppering can point to the diagnosis of LPLK, as in our case. Dermoscopically, in contrast to LPLK, LP demonstrates Wickham's striae, diffuse brown area, dotted vessels, and linear capillaries.<sup>[6]</sup>

The histopathology of LPLK is similar to that of LP and demonstrates lichenoid infiltrate, basal vacuolar degeneration, apoptotic keratocytes, hyperkeratosis, and hypergranulosis. The presence of focal parakeratosis and RBC extravasation is the discrimination features that are not observed in LP. Besides, in contrast to cutaneous LP, dermal eosinophils, neutrophils, and plasma cells are observed in LPLK. In the index case, mounds of parakeratosis were found in addition to all the classic features of LP, and no associated features of SL or SK were found.<sup>[1,7]</sup>

In conclusion, the clinical diagnosis of LPLK is difficult due to the lack of any characteristic clinical morphology, especially in the absence of associated SL or SK. A dermoscopic examination can be a reliable tool in revealing the diagnosis of LPLK in an appropriate clinical setting which can be confirmed by pathological examination.

#### Declaration of patient consent

The authors certify that they have obtained all appropriate patient consent.

#### Financial support and sponsorship

Nil.

#### Conflicts of interest

Dr. Devinder Mohan Thappa is the Editor-In-Chief of the journal.

#### REFERENCES

1. Vincek V. Lichen planus-like keratosis: Clinicopathological evaluation of 1366 cases. *Int J Dermatol* 2019;58:830-3.
2. Pogorzelska-Antkowiak A. Lichen planus-like keratosis: What do we know about? *Clin Exp Dermatol* 2022. Epub ahead of print
3. Ansari MS, Akay BN, Cengiz FP, Rosendahl N, Mahmoudi H, Daneshpazhooh M, *et al.* Clinical and dermatoscopic characteristics of lichen planus-like keratosis in a West-Asian population. *Australas J Dermatol* 2021;62:e55-61.
4. Elgart GW. Seborrheic keratoses, solar lentigines, and lichenoid keratoses. Dermoscopic features and correlation to histology and clinical signs. *Dermatol Clin* 2001;19:347-57.
5. Liopyris K, Navarrete-Dechent C, Dusza SW, Marghoob AA, Deng L, Wilson BB, *et al.* Clinical and dermoscopic features associated with lichen planus-like keratoses that undergo skin biopsy: A single-center, observational study. *Australas J Dermatol* 2019;60:e119-26.
6. Makhecha M, Singh T, Malladi N, Rambhia K. Dermoscopic features of various stages of lichen planus. *Indian J Dermatol Venereol Leprol* 2020;86:191-4.
7. Zaballo P, Martí E, Cuéllar F, Puig S, Malveyh J. Dermoscopy of lichenoid regressing seborrheic keratosis. *Arch Dermatol* 2006;142:410.

**How to cite this article:** Behera B, Kumari R, Thappa DM, Gochhait D. Dermoscopy: A reliable guide in the diagnosis of lichen planus-like keratosis in an appropriate clinical setting. *CosmoDerma* 2022;2:84.