

Review Article

## Tips for managing post-inflammatory hyperpigmentation of acne

Suruchi Garg<sup>1</sup>, Ankita Tuknayat<sup>1</sup>

<sup>1</sup>Department of Dermatology, Aura Skin Institute, Chandigarh, India.



**\*Corresponding author:**

Suruchi Garg,  
Department of Dermatology,  
Aura Skin Institute,  
Chandigarh, India.

[gargsuruchi01@gmail.com](mailto:gargsuruchi01@gmail.com)

Received : 24 May 2021  
Accepted : 22 June 2021  
Published : 23 July 2021

DOI  
10.25259/CSDM\_17\_2021

Quick Response Code:



### ABSTRACT

Post-inflammatory hyperpigmentation (PIH) is a reactive hypermelanosis, profoundly common in the Asian skin. The post-acne sequelae may have profound effects on the patients' mental status, sometimes even more than the acne itself, as they are long lasting and sometimes treatment refractory. PIH occurs secondary to release of inflammatory mediators such as prostaglandins and interleukins in acne which stimulate melanogenesis. There are a multitude of therapeutic modalities available for the treatment of PIH associated with acne. Treating acne and PIH simultaneously would be a logical approach. Epidermal PIH usually responds to topical skin lightening agents which are the first line in these cases. Patients refractory to topical and oral treatment modalities usually have dermal PIH and may be offered interventional therapies. These therapies can be utilized simultaneously along with conventional therapies to hasten up the results, as combination treatment works synergistically by multipronged action at different pathways of etiopathogenesis. The patients with dermal PIH refractory to standard treatment may require other adjunctive therapies such as chemical peels, PRP, and lasers. This review provides an insight into rational and holistic approach to the management of the underlying acne, early customized treatment along with correction of underlying nutritional deficiencies, and lifestyle modifications in effective treatment of PIH.

**Keywords:** Post-inflammatory hyperpigmentation, Acne, Skin lightening agents

### INTRODUCTION

Post-inflammatory hyperpigmentation (PIH) is a reactive hypermelanosis, profoundly common in the Asian skin.<sup>[1]</sup> It presents as diffuse brownish to tan-colored patch or multiple well-circumscribed macules depending on the underlying condition causing it.<sup>[2]</sup> One of the most common conditions causing PIH in about 60% of the patients is acne vulgaris. Acne vulgaris is a common chronic inflammatory disorder characterized by comedones, papules, pustules, and nodules in varying proportion affecting the face, back, and chest.<sup>[3]</sup> These sites, especially the face, are the visible sites, thus acne and its associated sequelae are a cause of significant psychological morbidity for the patients.<sup>[4]</sup> These sequelae may have a profound effect on the patients' mental status, sometimes even more than the acne itself, as they are long lasting and sometimes treatment refractory.<sup>[5,6]</sup> A number of therapeutic modalities are available for the treatment of PIH associated with acne.<sup>[7]</sup> The treatment of PIH can be addressed effectively along with the treatment of the underlying disorder.

### PATHOGENESIS OF PIH ASSOCIATED WITH ACNE

There are four factors which act in combination to result in acne: Increased sebaceous gland activity with seborrhea, abnormal follicular differentiation with increased keratinization,

This is an open-access article distributed under the terms of the Creative Commons Attribution-Non Commercial-Share Alike 4.0 License, which allows others to remix, tweak, and build upon the work non-commercially, as long as the author is credited and the new creations are licensed under the identical terms.

©2021 Published by Scientific Scholar on behalf of Cosmo Derma

microbial hypercolonization of the follicular canal, and increased inflammation.<sup>[8,9]</sup> The last factor, that is, increased inflammation is the basic causative factor in the pathogenesis of PIH [Figure 1].<sup>[10]</sup>

Perifollicular subclinical inflammation has been demonstrated in all the lesions of acne including microcomedones.<sup>[11]</sup> Thus, PIH can occur even in patients with predominantly comedonal acne.

Role of nutrition in acne and its associated PIH is controversial but a number of studies have demonstrated a significant advantage of high-protein diet and good nutrition in the management of such patients. Garg and Sangwan have found that high-carb-low-protein diet leads to perifollicular

inflammation and fibrosis. They proposed a “hypothesis of conscious selective self-destruction and non-renewal” or “deregulated autophagy” which means that when the body is depleted of important nutrients like proteins, it compensates by self-destruction of relatively non-essential tissues and deliberates delayed healing at sites like skin and hair tissues to conserve proteins for more active and vital tissue like muscles.<sup>[12]</sup> Besides high-protein diet, lifestyle modifications are also suggested such as avoiding prolonged starvations and skipping of meals as this type of lifestyle leads to more pigmentary disorders such as melasma, PIH, and periorbital hyperpigmentation (35%) in studied population (98 subjects) due to underlying macro- and micro-nutrient deficiencies. It

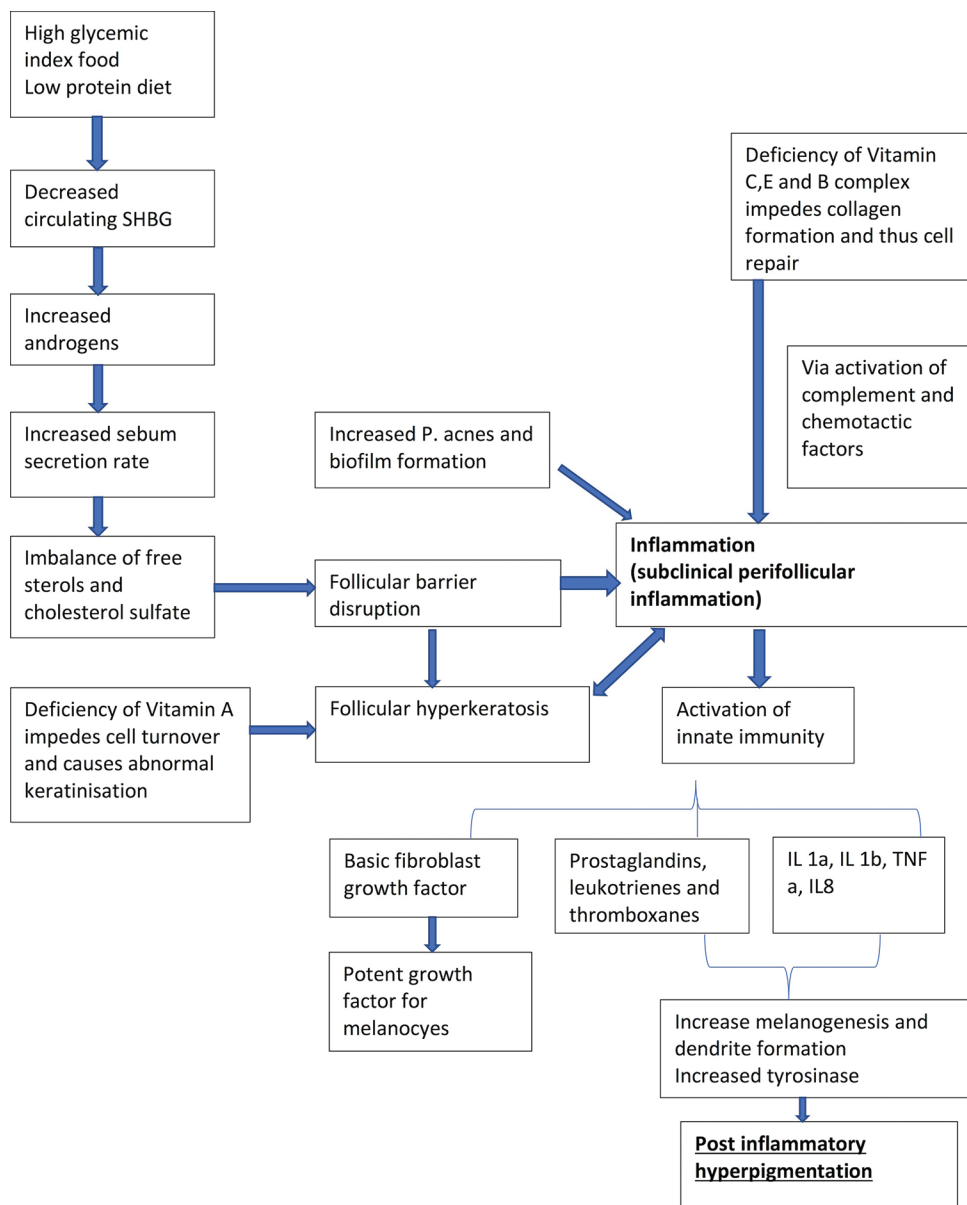


Figure 1: Pathogenesis of post-inflammatory hyperpigmentation.

was also recommended to have early morning protein and micronutrient balanced breakfast due to high nutritional demand due to morning hormonal surge and overnight starvation. This enables the body to reduce the starvation-induced stress and heals the damaged tissues without sequelae. Erratic eating habits also lead to micronutrient deficiencies thus aggravating the PIH further. This makes it imperative to test hemoglobin, Vitamin D, B12, thyroid function tests, and iron studies in all patients of PIH.<sup>[12]</sup>

### Detailed history and examination

Proper history should be taken from the patients. Examination would include evaluation of active acne and its associated complications at face, chest, and trunk. Hormonal profile should be ordered in patients with irregular menstruation, jawline distribution of the lesions, seborrhea, and hirsutism.<sup>[13]</sup> Other medical conditions such as polycystic ovarian disease, Cushing's syndrome, undue stress, or depression should be looked out for. Patients should also be asked about the intake of drugs possibly contributing to acne or PIH such as anticonvulsants, anabolic steroids, and antidepressants.<sup>[14]</sup>

### Differentiation between superficial/deep PIH

Clinically, PIH could be epidermal or dermal. Epidermal PIH usually occurs due to increase melanin formation while dermal PIH occurs due to break in basement membrane which leads to melanophage formation. Epidermal PIH usually presents as brown color while dermal is tan or bluish. Dermal PIH is more refractory to treatment.<sup>[14]</sup>

## TREATMENT

There are some basic do's and do not's to prevent and control PIH [Table 1]. There are a multitude of therapeutic modalities available for the treatment of PIH associated with acne [Figure 2]. Treating acne and PIH simultaneously would be a logical approach.<sup>[7]</sup> Thus, the ideal treatment would be a single agent that is effective against both acne and PIH. It is also pertinent to choose an agent which causes minimal irritation to the skin as this may lead to worsening of PIH rather than improvement. Value of photoprotection using a sunscreen with SPF of at least 30 cannot be underestimated. The treatment can be a spot treatment or field therapy depending on the area affected.<sup>[15]</sup>

Treatment options could be divided in medical and procedural modalities [Figure 3].

### Medical therapies

#### Topical agents

Topical depigmenting agents are usually the first line of therapy [Table 2]. They have a good response in epidermal

PIH but dermal PIH is usually refractory to these therapies.<sup>[15,16]</sup>

While retinoids and azelaic acid work effectively both on active acne and PIH, hydroquinone, kojic acid, niacinamide, Vitamin C, and liquorice extract are promising agents on PIH. Other newer agents such as rucinol, pycnogenol, ellagic acid,<sup>[17-33]</sup> and silymarin are usually used in combination with other depigmenting agents [Figure 4].<sup>[34]</sup>

#### Systemic agents

Systemic therapies are usually prescribed to the patients who are resistant to topical therapies or as add-on therapies for faster improvement [Table 3].<sup>[35-37]</sup>

Along with the above treatment options, oral isotretinoin has also been used to reduce the inflammation associated with acne as well as PIH.<sup>[38]</sup>

#### Interventional therapies

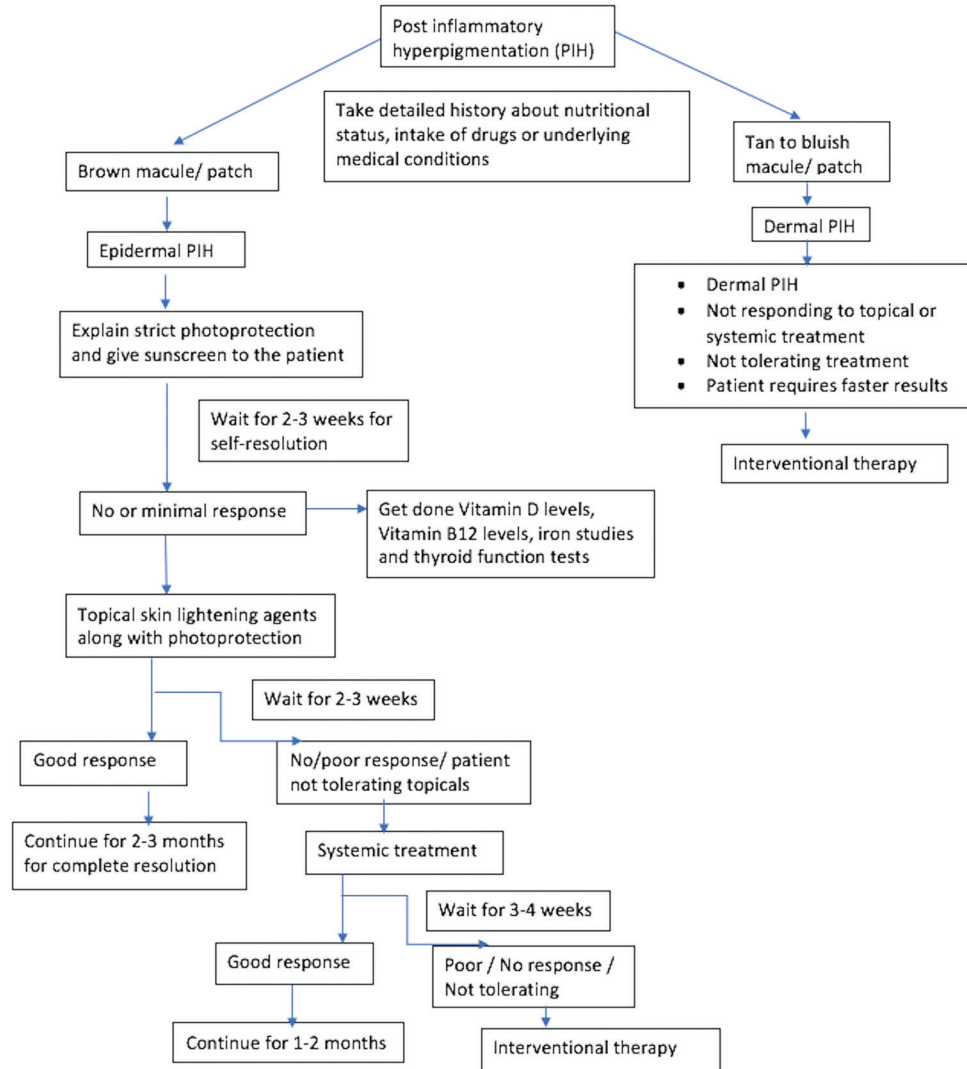
Patients refractory to topical and oral treatment modalities and those who have dermal PIH are the suggested patients for interventional therapies. These therapies can be utilized simultaneously along with conventional therapies to hasten up the results, as combination treatment works synergistically by multipronged action at different pathways of etiopathogenesis.

#### Chemical peels/chemexfoliation

Superficial chemical peels which penetrate into the papillary dermis are usually well tolerated in dark-skinned

**Table 1:** Do's and do not's while managing PIH.

Do's	Do not's
Adequate sun protection	Avoid excessive sun exposure
Proper nutrition should be maintained and any underlying deficiency should be corrected	Aggressive and over treatment should be avoided
Underlying disorder like acne should be simultaneously treated	Patients with undue expectations, body dysmorphic disorder, or hypochondrism should not be included
Proper detailed history regarding any history of medical diseases or drug intake should be taken for all the patients	
Psychological evaluation should be done	
Proper priming should be done before peeling	
Proper informed consent should be taken from the patient and expected results should be explained to him/her	



**Figure 2:** Approach to a patient of post-inflammatory hyperpigmentation.

individuals.<sup>[39]</sup> It is pertinent to use the correct type and percentage of peel so as to avoid irritation which can worsen PIH.

Tissue replacement is achieved by a controlled stage of inflammation.<sup>[40]</sup> The peels cause elimination of epidermal melanin and can also inhibit the transfer of melanosomes to keratinocytes. Medium- and high-depth peels can also be used but they have a high risk of causing PIH in dark-skinned individuals. The most important factor to consider before doing peeling in such patients is excellent priming which can be done with hydroquinone, retinoids, kojic acid, or glycolic acid (6–12%).<sup>[41]</sup>

Glycolic acid is a small molecular alpha-hydroxy acid, which at a concentration less than 30% disrupts enzymes such as sulfotransferases, phosphotransferases, and kinases, thereby reducing sulfate and phosphate groups from the surface of

keratinocytes decreasing corneocyte cohesions. Thus, it acts as a keratoregulator that increases corneocyte shedding and cell replacement. It usually acts above the granular layer and reduces the number of desmosomes and aggregation of tonofilaments.<sup>[42]</sup>

Lactic acid is a light weight acid which easily passes through the cell membrane. It has a keratolytic effect and has excellent hydrating properties, suitable even for hypersensitive skin.<sup>[41]</sup>

Mandelic acid is one of the largest alpha-hydroxy acids, which works in a similar way to decrease PIH.<sup>[43]</sup>

Retinoic acid peel, also known as yellow peel, contains tretinoin as the active component. It binds to the nuclear receptors which regulate cell differentiation, proliferation, and intercellular communication. In addition to this, it also exerts an anti-inflammatory effect and anti-comedonal effect.<sup>[43]</sup>

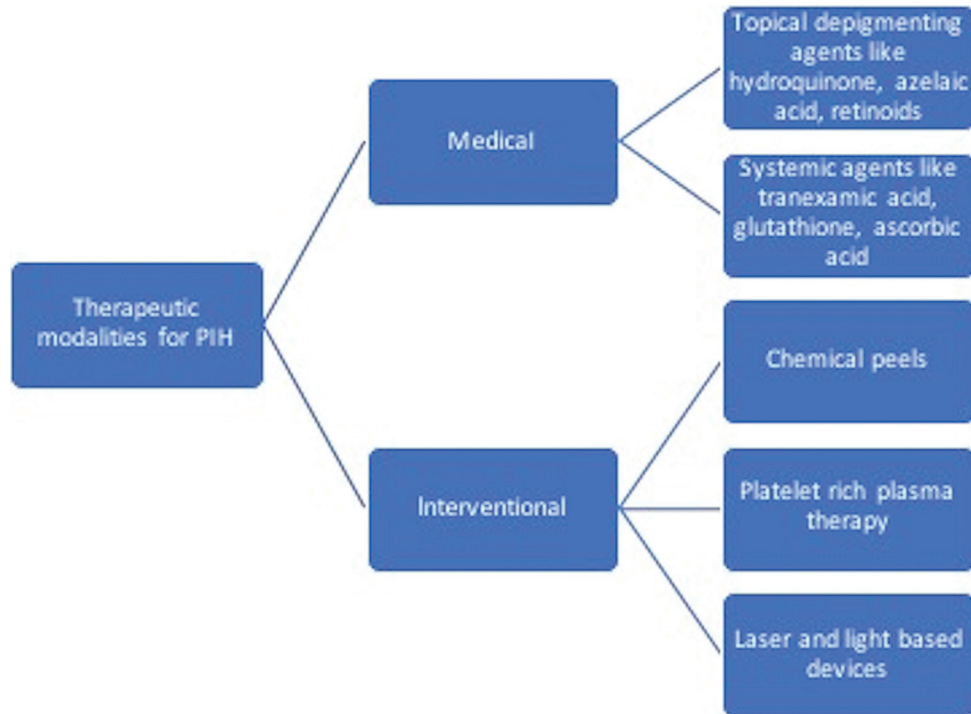


Figure 3: Therapeutic modalities for post-inflammatory hyperpigmentation.

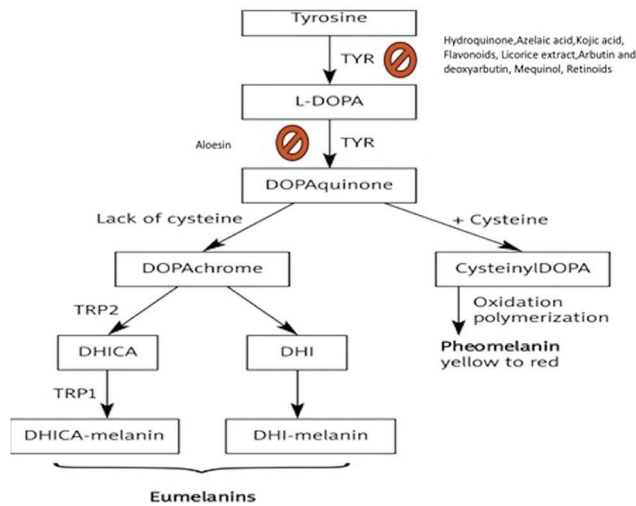


Figure 4: Pathway of melanin synthesis.

Salicylic acid is a beta-hydroxy acid which has a high affinity for lipids and removes intercellular lipids that are covalently linked to the cells, thus reducing sebum. It is regarded as a desmolytic agent because it disrupts the cellular junctions.<sup>[31]</sup> It affects the arachidonic acid cascade and has significant anti-inflammatory properties. Thus, it has effect on both acne and PIH.<sup>[44-46]</sup>

Jessner's solution contains 14% lactic acid, 14% salicylic acid, and 14% resorcinol in ethanol. It is used either alone or in

combination with trichloroacetic acid peel as a superficial peeling agent in PIH.<sup>[43]</sup>

Deep peels such as trichloroacetic acid and phenol are very effective for resistant type of pigmentation, but should be used with a lot of caution [Figure 5]. Phenol peel can also be combined with micro needling and radiofrequency [Figure 6]. These may lead to chemical burns and are specially not suited for sensitive skin types and nutritionally deficient patients.<sup>[47]</sup>

In addition, combination peels such as glycolic acid, kojic acid, and arginine work effectively in reducing PIH.<sup>[47]</sup> These have a good safety profile as lower concentrations are used and work for active acne as well [Figure 7]. All these peels are usually well tolerated by Fitzpatrick skin types IV to VI as individual concentration of each chemical is reduced and better controlled. These peels can also be combined with lasers [Figure 8]. If proper procedure and precautions are followed, there are minimal side effects which include transient erythema, burning sensation, reactivation of herpes simplex virus, and paradoxical PIH.

#### Platelet-rich plasma (PRP) therapy

PRP is an autologous product containing more than 94% platelets as compared to 6% in blood. Platelets contain more than 30 growth factors such as platelet-derived growth factor (PDGF), transforming growth factor (TGF) beta

**Table 2:** Topical skin lightening agents.

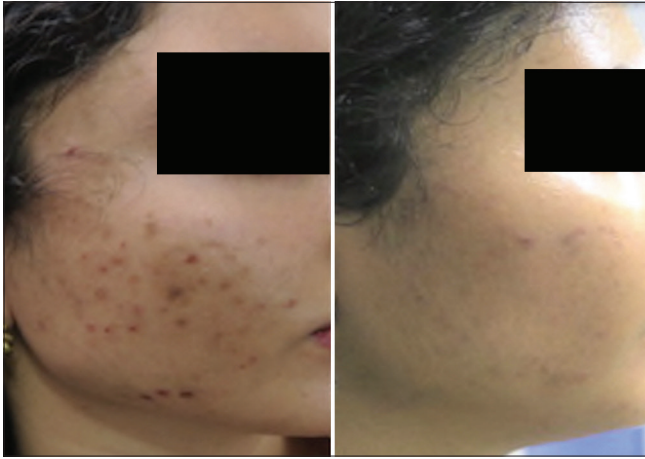Agent	Mechanism of action	Adverse effects
Hydroquinone <sup>[17,18]</sup>	Inhibits tyrosinase Inhibition of DNA and RNA synthesis Degradation of melanosomes Destruction of melanocytes	Contact dermatitis, exogenous ochronosis, halo hypopigmentation
Azelaic acid <sup>[19,20]</sup>	Inhibits tyrosinase Interferes with DNA synthesis Antiproliferative and cytotoxic effect on abnormal melanocytes	Irritation, transient erythema, burning
Retinoids <sup>[21,22]</sup>	Inhibits tyrosinase transcription; melanin dispersion/removal by increased epidermal turnover	Retinoid dermatitis
Mequinol <sup>[23-25]</sup>	A competitive inhibitor of tyrosinase	PIH, erythema, burning, desquamation, dryness
Kojic acid <sup>[26]</sup>	Inhibits tyrosinase (chelates copper at the active site of this enzyme)	Allergic contact dermatitis, erythema, stinging, mild exfoliation
Arbutin and deoxyarbutin <sup>[27]</sup>	Inhibits tyrosinase and melanosome maturation	PIH (higher concentrations), erythema
Niacinamide <sup>[28]</sup>	Inhibits melanosome transfer Decreases melanogenesis through cell signaling interference	Local skin reaction
N-acetyl glucosamine <sup>[15]</sup>	Inhibits tyrosinase glycosylation	Local skin reaction
Ascorbic acid (Vitamin C) <sup>[29]</sup>	Interrupts melanogenesis by interacting with copper ions to reduce dopaquinone	Local skin reaction (i.e., irritation)
Vitamin E (a-tocopherol acetate) <sup>[30]</sup>	Interferes with lipid peroxidation of melanocyte membranes Increase in intracellular glutathione content	Allergic or irritant reactions
Licorice extract (glabridin and liquiritin) <sup>[31]</sup>	Inhibits tyrosinase Melanin dispersion Anti-inflammatory properties	Erythema, burning
Soy <sup>[32]</sup>	Inhibits melanosome transfer (soybean trypsin inhibitor and Bowman-Birk inhibitor inhibit the activation of the PAR-2 cell receptors)	Erythema, burning, pruritus, dryness
Aloesin <sup>[33]</sup>	Competitively inhibits tyrosine hydroxylase and DOPA-oxidase	Irritant reactions
Flavonoids <sup>[15]</sup>	Antioxidant and anti-inflammatory effect Inhibits tyrosinase	Allergic or irritant reactions

**Table 3:** Systemic skin-lightening agents.

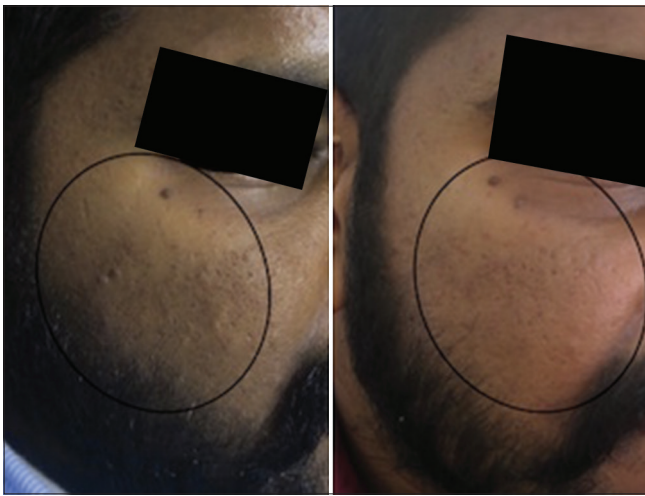
Agent	Mechanism of action	Adverse effects
Tranexamic acid <sup>[35]</sup>	Inhibits plasminogen activator from converting plasminogen to plasmin Decreases the release of basic fibroblast growth factor Decreases alpha-melanocyte-stimulating hormone	Nausea, diarrhea, abdominal pain, hypomenorrhea, skin rashes, drowsiness
Glutathione <sup>[36,37]</sup>	Directly or indirectly inhibiting tyrosinase activity (binds to active site of the enzyme containing copper and eliminates free radicals and peroxides)	Long-term safety has not been demonstrated
Pycnogenol (procyanidin) <sup>[34]</sup>	Anti-inflammatory and antioxidant Inhibits NF-KB	Metallic taste
Polypodium leucotomos <sup>[34]</sup>	Antioxidant and photoprotective properties	No serious side effects

1 and 2, epidermal growth factor (EGF), platelet-derived angiogenesis factor, and fibrinogen.<sup>[48]</sup> These growth factors play a role in various homeostatic mechanisms of the body.

Two of these growth factors have demonstrated a significant role in reduction of hyperpigmentation. TGF decreases melanogenesis by downregulating microphthalmia-



**Figure 5:** Phenol light peel before and after four sessions.

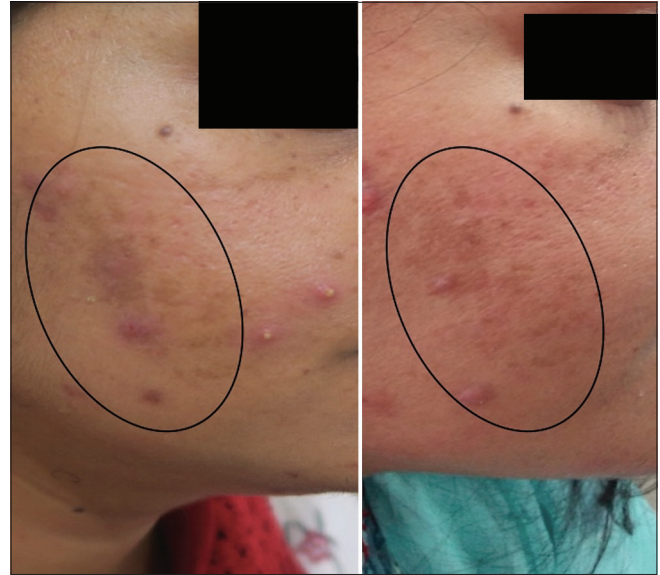

**Figure 6:** Phenol light peel and microneedling radiofrequency before and after two sessions each.

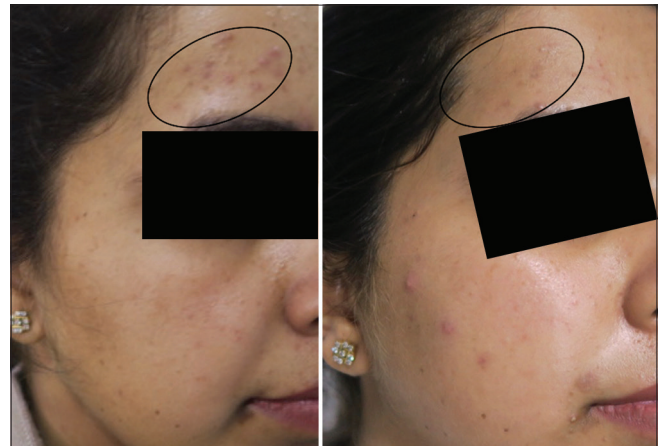
associated transcription factor promoter activity and inhibiting the expression of paired box homeo-c gene (PAX 3), which at the protein level, reduces the production of tyrosinase and tyrosinase-related protein 1 and 2.<sup>[49]</sup> EGF inhibits prostaglandin-E2 (PGE2) expression and tyrosinase enzyme activity. PRP can be injected or used along with dermarollers, microneedling radiofrequency, and lasers.<sup>[50]</sup>

### **Laser- and light-based therapies**

Although topical skin-lightening agents are the first-line treatment for PIH, some patients with dermal pigmentation may be refractory to treatment. Such patients require alternative or adjunctive therapies. Laser- and light-based therapies have been used in a few such cases but these have to be used very cautiously for PIH as if not used judiciously, these may paradoxically cause PIH.<sup>[51]</sup>



**Figure 7:** Combination peel (glycolic, kojic, and lactic acid peel) before and after two sessions each.



**Figure 8:** SSR 540 laser and combination peel (arginine, kojic, and lactic acid peel) before and after two sessions each.

The basis for using these therapies is selective photothermolysis and that green, red, or near-infrared lasers are pigment specific and these lights selectively target intracellular melanosomes.<sup>[52]</sup> A selective window for targeting melanin lies between 630 and 1100 nm, where there is good skin penetration and preferential absorption of melanin over oxyhemoglobin.<sup>[53]</sup> Typically, energy from short wavelength lasers is more efficiently absorbed by epidermal melanin while longer wavelengths penetrate deeper with more selective absorption by dermal targets making them safer to use for darker skin patients. The use of longer pulse durations and cooling devices can also provide a greater margin of safety while maintaining efficacy in darker-skinned individuals.<sup>[53]</sup>

Shorter wavelengths (<600 nm) damage pigmented cells with lower energy fluencies, while longer wavelengths (>600 nm) penetrate deeper but need more energy to cause melanosome damage. Besides wavelength, pigment specificity of lasers also depends on pulse width. With an estimated thermal relaxation time of 250–1000 ns, melanosomes require submicrosecond laser pulses (<1  $\mu$ s) for their selective destruction, but longer pulse durations in the millisecond domain do not appear to cause specific melanosome damage.<sup>[54]</sup>

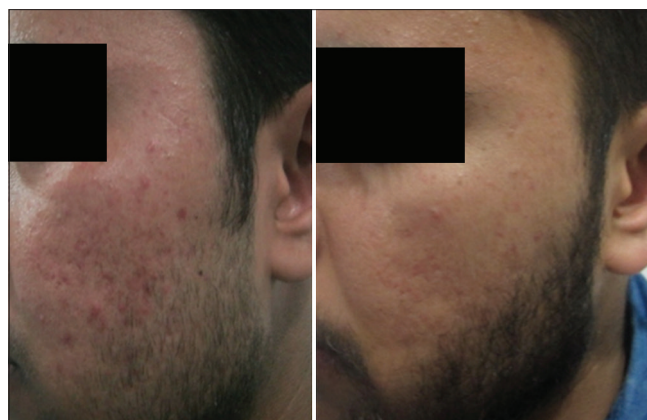Acne laser blue light can be used for active acne as well as PIH [Figure 6]. Blue light not only targets the propionibacterium acne but also improves PIH and erythema. The 1064 nm QS-Nd: YAG is well absorbed by melanin and being a longer wavelength causes minimal damage to epidermis and is not absorbed by hemoglobin. The deeper skin penetration is also helpful to target dermal melanin.<sup>[55]</sup> Low-dose QS Nd: YAG laser induces sublethal injury to melanosomes causing fragmentation and rupture of melanin granules into the cytoplasm.<sup>[56]</sup> This effect is highly selective for melanosomes as this wavelength is well absorbed by melanin relative to other structures.<sup>[45]</sup> Different platforms utilize different fluence, pulse width, and frequency for optimum results. The fluence used is less than 1.9–2.6 J/cm<sup>2</sup>, spot size 6 mm, and frequency of 10 Hz.<sup>[57]</sup>

## FRACTIONAL NON-ABLATIVE AND ABLATIVE LASERS

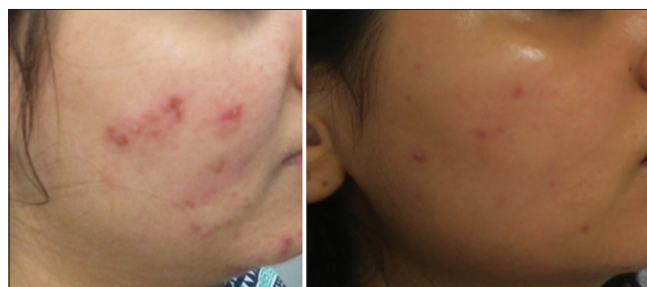This is a new concept in laser therapy in which multiple microscopic zones of thermal damage are created leaving the majority of the skin intact.<sup>[58,59]</sup> The latter serves as a reservoir for healing. These multiple columns of thermal damage are called microthermal treatment zones (MTZ) and lead to extrusion of microscopic epidermal necrotic debris (MEND) that includes pigment in the basal layer.<sup>[60]</sup> The viable keratinocytes at the wound margins facilitate the migration of MENDs. The depth and diameter of MTZ are determined by the energy levels used. In non-ablative erbium glass laser, there are no visibly ablative zones but only microscopic columns of damage.<sup>[61]</sup> There is virtually zero down time and only mild erythema and swelling are visible. Hence, the recovery is faster and complications of open wounds such as hyper- or hypo-pigmentation are avoided.<sup>[62]</sup> In ablative lasers (erbium YAG 2940 and CO<sub>2</sub> laser), on the other hand, healing time is 5–7 days with crusting and exfoliation [Figure 9]. The stratum corneum is found to be intact after 24 h of treatment. There is less risk of scarring, in fact, use of ablative lasers leads to improvement of post-acne scars. Sensitive areas such as neck and chest that are more prone to scarring can be safely treated with lesser fluence and less number of passes. Furthermore, greater depths of penetration can be achieved as entire skin surface is not ablated hence, dermal PIH can be targeted.<sup>[63]</sup>

IPL was developed in the late 1990s and involves the use of a xenon-chloride lamp that emits light that is non-coherent not collimated and has a wide spectrum (500–1200 nm).<sup>[64]</sup> The advantage of IPL lies in the flexibility of parameters. The effectiveness of IPL involves absorption of light energy by melanin in keratinocytes and melanocytes leading to epidermal coagulation due to photothermolysis followed by microcrust formation. These crusts containing melanin are shed off, hence, the clinical improvement in pigmentation. The newer IPL-based technologies have the flexibility of lower fluence and higher pulse width, thus leading to effective results topped with safety and virtually no down time. Figure 10 interestingly shows marked improvement with ACNE 420 blue light not only in active acne but also on redness and PIH without any signs of post-acne scarring. Another added advantage with the wavelengths below 600 nm is that they also target oxyhemoglobin leading to improvement in post-acne erythema besides improving PIH.<sup>[64]</sup>

Combination therapy is that in which different modalities of treatment are combined according to the patients' needs and skin type. It is usually done when the patient has lesser time, that is, some important life event is coming up, the pigmentation appears dermal and the pigmentation is refractory to unimodal treatment.



**Figure 9:** Pixel erbium YAG laser before and after three sessions.



**Figure 10:** Acne 420 laser for active acne and PIH before and after three sessions.



## CONCLUSION

PIH secondary to acne is a long-lasting and psychologically distressing problem in dark-skinned individuals. It occurs secondary to release of inflammatory mediators such as prostaglandins and interleukins in acne which stimulate melanogenesis. Epidermal PIH usually responds to topical skin-lightening agents which are the first line in these cases. Some patients with dermal PIH refractory to standard treatment may require other adjunctive therapies such as chemical peels, PRP, and lasers. Rational and holistic approach to the management of the underlying acne, early customized treatment along with correction of underlying nutritional deficiencies, and lifestyle modifications plays the most crucial role in effective treatment of PIH.

## Declaration of patient consent

The authors certify that they have obtained all appropriate patient consent.

## Financial support and sponsorship

Nil.

## Conflicts of interest

There are no conflicts of interest.

## REFERENCES

- Davis EC, Callender VD. Postinflammatory hyperpigmentation: A review of the epidemiology, clinical features, and treatment options in the skin of colour. *J Clin Aesthet Dermatol* 2010;3:20-31.
- Callender VD, St Surin-Lord S, Davis EC, Maclin M. Postinflammatory hyperpigmentation: Etiologic and therapeutic considerations. *Am J Clin Dermatol* 2011;12:87-99.
- Dreno B, Poli F. Epidemiology of acne. *Dermatology* 2003;206:7-10.
- França K, Keri J. Psychosocial impact of acne and post inflammatory hyperpigmentation. *An Bras Dermatol* 2017;92:505-9.
- Akinboro AO, Ezejiofor OI, Olanrewaju FO, Oripelaye MM, Olabode OP, Ayodele OE, *et al.* The impact of acne and facial post-inflammatory hyperpigmentation on quality of life and self-esteem of newly admitted Nigerian undergraduates. *Clin Cosmet Investig Dermatol* 2018;11:245-52.
- Goh CL, Abad-Casintahan F, Chow SK, Kubba R, Miyachi Y, Noppakun N, *et al.* Evaluating acne-related post-inflammatory hyperpigmentation is a challenge even amongst experts. *J Dermatol* 2014;41:1106-8.
- Levin J. The relationship of proper skin cleansing to pathophysiology, clinical benefits, and the concomitant use of prescription topical therapies in patients with acne vulgaris. *Dermatol Clin* 2016;34:133-45.
- Degitz K, Placzek M, Borelli C, Plewig G. Pathophysiology of acne. *J Dtsch Dermatol Ges* 2007;5:316-23.
- Lavker RM, Leyden JJ, McGinley KJ. The relationship between bacteria and the abnormal follicular keratinization in acne vulgaris. *J Invest Dermatol* 1981;77:325-30.
- Tomita Y, Maeda K, Tagami H. Melanocyte-stimulating properties of arachidonic acid metabolites: Possible role in postinflammatory pigmentation. *Pigment Cell Res* 1992;5:357-61.
- Jeremy AH, Holland DB, Roberts SG, Thomson KF, Cunliffe WJ. Inflammatory events are involved in acne lesion initiation. *J Invest Dermatol* 2003;121:20-7.
- Garg S, Sangwan A. Dietary protein deficit and deregulated autophagy: A new clinico-diagnostic perspective in pathogenesis of early aging, skin, and hair disorders. *Indian Dermatol Online J* 2019;10:115-24.
- Abad-Casintahan F, Chow SK, Goh CL, Kubba R, Hayashi N, Noppakun N, *et al.* Frequency and characteristics of acne-related post-inflammatory hyperpigmentation. *J Dermatol* 2016;43:826-8.
- Taylor SC, Grimes PE, Lim J, Im S, Lui H. Postinflammatory hyperpigmentation. *J Cutan Med Surg* 2009;13:183-9.
- Halder RM, Richards GM. Topical agents used in the management of hyperpigmentation. *Skin Therapy Lett* 2004;9:1-3.
- Stratigos AJ, Katsambas AD. Optimal management of recalcitrant disorders of hyperpigmentation in dark-skinned patients. *Am J Clin Dermatol* 2004;5:161-8.
- Cook-Bolden FE, Hamilton SF. An open-label study of the efficacy and tolerability of microencapsulated hydroquinone 4% and retinol 0.15% with antioxidants for the treatment of hyperpigmentation. *Cutis* 2008;81:365-71.
- Jimbow K, Minamitsuji Y. Topical therapies for melasma and disorders of hyperpigmentation. *Dermatol Ther* 2001;14:35-45.
- Kircik LH. Efficacy and safety of azelaic acid (AzA) gel 15% in the treatment of post-inflammatory hyperpigmentation and acne: A 16-week, baseline-controlled study. *J Drugs Dermatol* 2011;10:586-90.
- Sarkar R, Bhalla M, Kanwar KJ. A comparative study of 20% azelaic acid cream monotherapy versus a sequential therapy in the treatment of melasma in dark-skinned patients. *Dermatology* 2002;205:249-54.
- Bulengo-Ransby SM, Griffiths C, Kimbrough-Green CK, Finkel LJ, Hamilton TA, Ellis CN, *et al.* Topical tretinoin (retinoic acid) therapy for hyperpigmented lesions caused by inflammation of the skin in black patients. *N Engl J Med* 1993;328:1438-43.
- Grimes P, Callender V. Tazarotene cream for postinflammatory hyperpigmentation and acne vulgaris in darker skin: A double-blind, randomized, vehicle-controlled study. *Cutis* 2006;77:45-50.
- Jarratt M. Mequinol 2%/tretinoin 0.01% solution: An effective and safe alternative to hydroquinone 3% in the treatment of solar lentigines. *Cutis* 2004;74:319-22.
- Taylor SC, Callender VD. A multicenter, 12-week, phase 3b trial: A combination solution of mequinol 2%/tretinoin 0.01% 60. vs hydroquinone 4% cream in the treatment of mild to moderate postinflammatory hyperpigmentation. *J Am Acad Dermatol* 2006;54:AB194.
- Piacquadio D, Farris P, Downie J, Rendon M. Mequinol 2%/tretinoin 0.01% topical solution monotherapy and combination

- treatment of solar lentigines and postinflammatory hyperpigmentation. *J Am Acad Dermatol* 2004;52:P145.
26. Lim JT. Treatment of melasma using kojic acid in a gel containing hydroquinone and glycolic acid. *Dermatol Surg* 1999;25:282-4.
  27. Boissy RE, Visscher M, deLong MA. Deoxyarbutin: A novel reversible tyrosinase inhibitor with effective *in vivo* skin lightening potency. *Exp Dermatol* 2005;14:601-8.
  28. Hakozaiki T, Minwalla L, Zhuang J, Chhoa M, Matsubara A, Miyamoto K, *et al.* The effect of niacinamide on reducing cutaneous pigmentation and suppression of melanosome transfer. *Br J Dermatol* 2002;147:20-31.
  29. Farris, PK. Topical Vitamin C: A useful agent for treating photoaging and other dermatologic conditions. *Dermatol Surg* 2005;31:814-8.
  30. Lin JY, Selim MA, Shea CR, Grichnik JM, Omar MM, Monteiro-Riviere NA, *et al.* UV photoprotection by combination topical antioxidants Vitamin C and Vitamin E. *J Am Acad Dermatol* 2003;48:866-74.
  31. Yokota T, Nishio H, Kubota Y, Mizoguchi M. The inhibitory effect of glabridin from licorice extracts on melanogenesis and inflammation. *Pigment Cell Res* 1998;11:355-61.
  32. Paine C, Sharlow E, Liebel F, Eisinger M, Shapiro S, Seiberg M. An alternative approach to depigmentation by soybean extracts via inhibition of the PAR-2 pathway. *J Invest Dermatol* 2001;116:587-95.
  33. Choi S, Lee SK, Kim JE, Chung MH, Park YI. Aloesin inhibits hyperpigmentation induced by UV radiation. *ClinExp Dermatol* 2002;27:513-5.
  34. Grimes PE, Ijaz S, Nashawati R, Kwak D. New oral and topical approaches for the treatment of melasma. *Int J Womens Dermatol* 2018;5:30-6.
  35. Wang JV, Jhavar N, Saedi N. Tranexamic acid for melasma: Evaluating the various formulations. *J Clin Aesthet Dermatol* 2019;12:E73-4.
  36. Sitohang IB, Ninditya S. Systemic glutathione as a skin-whitening agent in adult. *Dermatol Res Pract* 2020;2020:8547960.
  37. Arjinpathana N, Asawanonda P. Glutathione as an oral whitening agent: A randomized, double-blind, placebo-controlled study. *J Dermatolog Treat* 2012;23:97-102.
  38. Winhoven SM, Ahmed I, Owen CM, Lear JT. Postinflammatory hyperpigmentation in an Asian patient: A dramatic response to oral isotretinoin (13-cis-retinoic acid). *Br J Dermatol* 2005;152:368-9.
  39. Roberts WE. Chemical peeling in ethnic/dark skin. *Dermatol Ther* 2004;17:196-205.
  40. Song JY, Kang HA, Kim MY, Park YM, Kim HO. Damage and recovery of skin barrier function after glycolic acid chemical peeling and crystal microdermabrasion. *Dermatol Surg* 2004;30:390-4.
  41. Grimes PE, Rendon MI, Pellerano J. Superficial chemical peels. In: Grimes PE, editor. *Aesthetics and Cosmetic Surgery for Darker Skin Types*. Philadelphia, PA: Lippincott Williams and Wilkins; 2008. p. 154-69.
  42. Burns RL, Prevost-Blank PL, Lawry MA, Lawry TB, Faria DT, Fivenson DP. Glycolic acid peels for postinflammatory hyperpigmentation in black patients. A comparative study. *Dermatol Surg* 1997;23:171-4; discussion 175.
  43. Sarkar R, Arsiwala S, Dubey N, Sonthalia S, Das A, Arya L, *et al.* Chemical peels in melasma: A review with consensus recommendations by Indian pigmentary expert group. *Indian J Dermatol* 2017;62:578-84.
  44. Ahn HH, Kim IH. Whitening effect of salicylic acid peels in Asian patients. *Dermatol Surg* 2006;32:372-5.
  45. Mohamed Ali BM, Gheida SF, El Mahdy NA, Sadek SN. Evaluation of salicylic acid peeling in comparison with topical tretinoin in the treatment of postinflammatory hyperpigmentation. *J Cosmet Dermatol* 2017;16:52-60.
  46. Joshi S, Boone S, Alam M, Yoo S, White L, Rademaker A, *et al.* Effectiveness, safety, and effect on quality of life of topical salicylic acid peels for treatment of postinflammatory hyperpigmentation in dark skin. *Am Soc Dermatol Surg* 2009;35:638-44.
  47. Taylor SC, Burgess CM, Callender VD, Fu J, Rendon MI, Roberts WE, *et al.* Postinflammatory hyperpigmentation: Evolving combination treatment strategies. *Cutis* 2006;78 Suppl 2:6-19.
  48. Gamea MM, Kamal DA, Donia AA, Hegab DS. Comparative study between topical tranexamic acid alone versus its combination with autologous platelet rich plasma for treatment of melasma. *J Dermatol Treat* 2020;Jun 22:1-7.
  49. Kim D, Park S, Park K. Transforming growth factor-1 decreases melanin synthesis via delayed extracellular signal-regulated kinase activation. *Int J Biochem Cell Biol* 2004;36:1482-91.
  50. Tuknayat A, Thami GP, Bhalla M, Sandhu JK. Autologous intralesional platelet rich plasma improves melasma. *Dermatol Ther* 2021;34:e14881.
  51. Tanzi EL, Alster TS. Cutaneous laser surgery in darker skin phototypes. *Cutis* 2004;73:27-30.
  52. Arora P, Sarkar R, Garg VK, Arya L. Lasers for treatment of melasma and post-inflammatory hyperpigmentation. *J Cutan Aesthet Surg* 2012;5:93-103.
  53. Anderson RR, Margolis RJ, Watanabe S, Flotte T, Hruza GJ, Dover JS. Selective photothermolysis of cutaneous pigmentation by Q-switched Nd: YAG laser pulses at 1064, 532, and 355 nm. *J Invest Dermatol* 1989;93:28-32.
  54. Sarkar R, Aurangabadkar S, Salim T, Das A, Shah S, Majid I, *et al.* Lasers in melasma: A review with consensus recommendations by Indian pigmentary expert group. *Indian J Dermatol* 2017;62:585-90.
  55. Park KY, Kim DH, Kim HK, Li K, Seo SJ, Hong CK. A randomized, observer-blinded comparison of combined 1064 nm Q-switched neodymium-doped yttrium aluminium laser plus glycolic acid peel vs. laser monotherapy to treat melasma. *Clin Exp Dermatol* 2011;864-70.
  56. Choi M, Choi JW, Lee SY, Choi SY, Park HJ, Park KC, *et al.* Low-dose 1064-nm Q-switched Nd: YAG laser for the treatment of melasma. *J Dermatol Treat* 2010;21:224-8.
  57. Suh KS, Sung JY, Roh HJ, Jeon YS, Kim YC, Kim ST. Efficacy of the 1064-nm Q-switched Nd: YAG laser for melasma. *J Dermatolog Treat* 2011;22:233-8.
  58. Cho SB, Park SJ, Kim JS, Kim MJ, Bu TS. Treatment of post-inflammatory hyperpigmentation using 1064-nm Q-switched Nd: YAG laser with low fluence: Report of three cases. *J Eur Acad Dermatol Venereol* 2009;23:1206-7.

59. Katz TM, Goldberg LH, Firoz BF, Friedman PM. Fractional photothermolysis for the treatment of postinflammatory hyperpigmentation. *Dermatol Surg* 2009;35:1844-8.
60. Naito SK. Fractional photothermolysis treatment for resistant melasma in Chinese females. *J Cosmet Laser Ther* 2007;9:161-3.
61. Tannous ZS, Astner S. Utilizing fractional resurfacing in the treatment of therapy-resistant melasma. *J Cosmet Laser Ther* 2005;7:39-43.
62. Rokhsar CK, Ciocon DH. Fractional photothermolysis for the treatment of postinflammatory hyperpigmentation after carbon dioxide laser resurfacing. *Dermatol Surg* 2009;35:535-7.
63. Oram Y, Akkaya AD. Refractory postinflammatory hyperpigmentation treated fractional CO<sub>2</sub> laser. *J Clin Aesthet Dermatol* 2014;7:42-4.
64. Park JM, Tsao H, Tsao S. Combined use of intense pulsed light and Q-switched ruby laser for complex dyspigmentation among Asian patients. *Lasers Surg Med* 2008;40:128-33.

**How to cite this article:** Garg S, Tuknayat A. Tips for managing post-inflammatory hyperpigmentation of acne. *CosmoDerma* 2021;1:28.