

## Visual Treats in Dermatology

# Bullous larva migrans with a string-of-pearls appearance

Aravind Sivakumar<sup>1</sup>, Arun Philips<sup>1</sup>

<sup>1</sup>Department of Dermatology, JIPMER, Puducherry, India.



**\*Corresponding author:**

Aravind Sivakumar,  
Department of Dermatology,  
JIPMER, Puducherry, India.  
[aravinddermat@gmail.com](mailto:aravinddermat@gmail.com)

Received: 30 September 2023

Accepted: 04 October 2023

Published: 18 October 2023

**DOI**

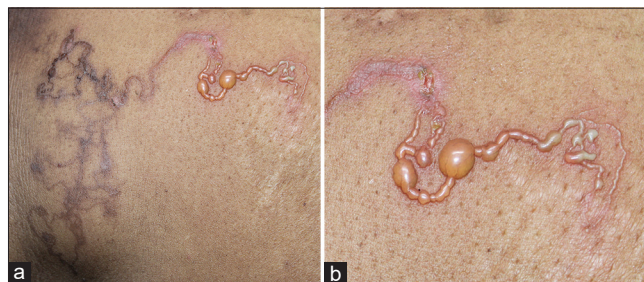
10.25259/CSDM\_201\_2023

**Quick Response Code:**



A woman in her fifties presented with itchy fluid-filled lesions over the chest for 1-month duration. She was a diagnosed case of metastatic breast carcinoma on neoadjuvant chemotherapy with docetaxel and trastuzumab along with radiotherapy. She noticed these lesions initially along the right inframammary area which slowly advanced to the epigastric region over 1 month. There were no systemic complaints. History of barefoot walking and lying on sand was present. On examination, there was a single well-defined erythematous serpiginous tract with overlying vesicles and bullae arranged in a “string-of-pearls” configuration over the abdomen [Figure 1a and b]. The patient was treated for cutaneous larva migrans with ivermectin for 2 consecutive days, following which lesions resolved after 1 week.

Cutaneous larva migrans also known as creeping eruption is an infestation caused by the animal hookworms unable to complete the lifecycle in the human accidental host. The infestation is acquired through contact with contaminated soil mainly in the tropics. It is characterized by the classical morphology of migratory serpiginous or curvilinear tracts caused by the larval migration beneath the skin. It needs to be clinically differentiated from larva currens or racing larvae caused by *Strongyloides stercoralis* which migrates much faster at the rate of 5–15 cm/h. Bullous lesions are an atypical manifestation in larva migrans and are usually due to larval products such as metalloproteinases and hyaluronidase, or due to type 4 hypersensitivity to the larval antigens.<sup>[1]</sup> The “string-of-pearls” or “clusters of jewels” sign refers to the grouped vesiculation in a background of erythema usually circumscribed or linear described classically in chronic bullous disease of childhood or linear immunoglobulin A bullous dermatoses. It is not specific and can be seen in other bullous dermatoses with similar configuration such as bullous



**Figure 1:** (a) Serpiginous linear eruptions over the abdomen. (b) “String-of-pearls” appearance of the serpiginous tract with overlying vesiculation and bullae.

This is an open-access article distributed under the terms of the Creative Commons Attribution-Non Commercial-Share Alike 4.0 License, which allows others to remix, transform, and build upon the work non-commercially, as long as the author is credited and the new creations are licensed under the identical terms.

©2023 Published by Scientific Scholar on behalf of CosmoDerma

pemphigoid and congenital syphilis.<sup>[2]</sup> Similar terminology has been used for the arrangement of eggs in the burrows of scabies, the beaded appearance of eyelids in Urbach–Wiethe disease, and dome-shaped pearly penile papules. Monilethrix is an inherited hair defect characterized by regular nodes and internodes derived from the Greek word “*momle*” which means necklace or string-of-pearls.<sup>[3]</sup> Hence, we report this case to highlight the string-of-pearls appearance of bullous larva migrans adding to this exhaustive list.

#### **Declaration of patient consent**

Patient’s consent not required as patient’s identity is not disclosed or compromised.

#### **Financial support and sponsorship**

Nil.

#### **Conflicts of interest**

There are no conflicts of interest

#### **Use of artificial intelligence (AI)-assisted technology for manuscript preparation**

The authors confirm that there was no use of Artificial Intelligence (AI)-assisted technology for assisting in the writing or editing of the manuscript and no images were manipulated using AI.

#### **REFERENCES**

1. Mathews J, Naseem JA, Neupane N, Parameswaran N, Chandrashekar L. An unusual presentation of early congenital syphilis with annular configuration of blisters resembling “string-of-pearls”. *Pediatr Dermatol* 2019;36:735-6.
2. Vijayasankar P, Subramaniam R, Kaliaperumal K. Bullous Cutaneous larva migrans of the palm. *Am J Trop Med Hyg* 2022;106:1298-9.
3. Klimas NK. A strand on strings of pearls. *J Cutan Med Surg* 2018;22:646.

**How to cite this article:** Sivakumar A, Philips A. Bullous larva migrans with a string-of-pearls appearance. *CosmoDerma* 2023;3:145.