

Innovations

Expanding horizons of the uses of chalazion clamp

Bhavya Swarnkar¹, Avik Mondal¹, Somesh Gupta¹

¹Department of Dermatology, All India Institute of Medical Sciences, New Delhi, India.



***Corresponding author:**

Bhavya Swarnkar,
Department of Dermatology,
All India Institute of Medical
Sciences, New Delhi, India.
swarnkarbhavya92@gmail.com

Received : 28 October 2022
Accepted : 07 November 2022
Published : 28 November 2022

DOI
10.25259/CSDM_129_2022

Videos available online at
[https://doi.org/10.25259/
CSDM_129_2022](https://doi.org/10.25259/CSDM_129_2022)

Quick Response Code:



PROBLEM

Due to lack of immobilization and adequate surrounding pressure around the lesion, there is a risk of dissipation of a sclerosing agent beyond the target area during sclerotherapy, leading to complications like Nicolau syndrome.^[1] Immobilization and central pressure are also important while enucleating corn's central nidus or removing the central deeper component of lesions like verruca.

SOLUTION

For a long time, the Chalazion clamp has been used to assist dermatological procedures such as ear lobe repair, oral mucosal procedures, nasal alae, and scrotal surgeries. The advantages of its use include hemostasis, a firm immobile surface to operate on, maintaining a firm grip on a slippery surface like mucosa, and easy manipulation of the surgical site.^[2] We extended the use of a chalazion clamp in preventing dissipation of the sclerosing agent beyond the required target while performing sclerotherapy over sites like fingers [Figure 1 and Video 1], toes (except the great toe due to the limited opening of the clamp), lips, and buccal mucosa. It immobilized the operating area and pressed the surrounding blood vessels, thereby preventing dissipation. We also used it while performing procedures such as paring and radiofrequency ablation of corn, callosity, and verruca over fingers and toes [Figure 2]. It helped in the procedure by providing a

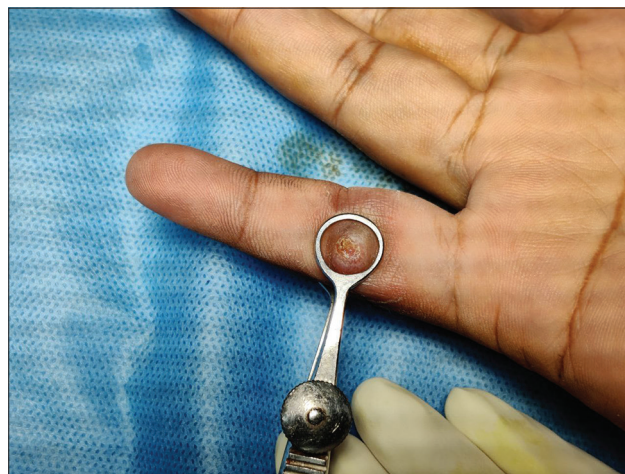


Figure 1: Image showing a pyogenic granuloma over a finger held by a chalazion clamp.

This is an open-access article distributed under the terms of the Creative Commons Attribution-Non Commercial-Share Alike 4.0 License, which allows others to remix, transform, and build upon the work non-commercially, as long as the author is credited and the new creations are licensed under the identical terms.

©2022 Published by Scientific Scholar on behalf of CosmoDerma

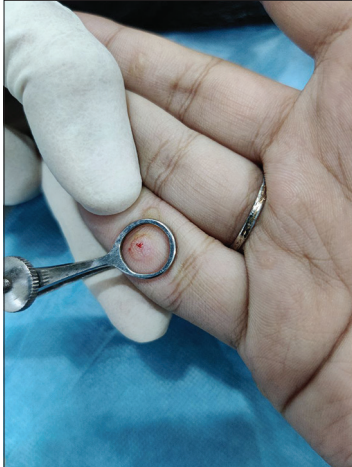

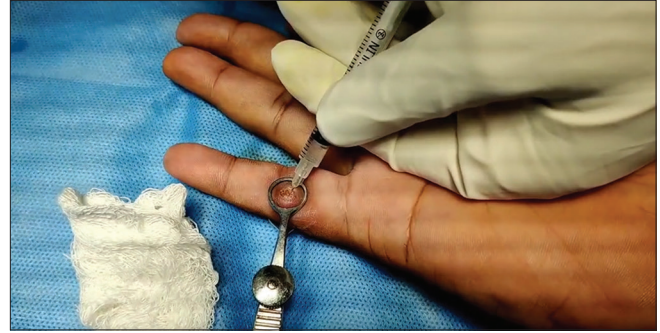Figure 2: Post-paring image of verruca over a finger, held by chalazion clamp.

firm immobile surface and protruding the central core of corn and the deeper part of callosity and verruca by compressing the center of the lesion. This made the procedure quite convenient, fast, and easy.

The use of this easily available and inexpensive instrument can make minor dermatosurgical procedures simple and prevent certain complications.

Declaration of patient consent

Patients' consent not required as patients' identity is not disclosed or compromised.



Video 1: Sclerotherapy is being performed over the finger while holding it using a chalazion clamp, to prevent dissipation of a sclerosing agent.

Financial support and sponsorship

Nil.

Conflicts of interest

There are no conflicts of interest.

REFERENCES

1. Deshmukh NS, Belgaumkar VA, Chavan RB, Bhatt N. Nicolau syndrome following intralesional sclerotherapy: A dreaded complication of a simple office procedure. *J Skin Stem Cell* 2020;7:e107198.
2. Jha AK, Ganguly S. Chalazion clamp in dermatology revisited. *Indian J Dermatol Venereol Leprol* 2015;81:280.

How to cite this article: Swarnkar B, Mondal A, Gupta S. Expanding horizons of the uses of chalazion clamp. *CosmoDerma* 2022;2:119.