

## Visual Treats in Dermatology

# Klippel–Trenaunay syndrome

Kanmani Indra Couppoussamy<sup>1</sup>, Rajendra Devanda<sup>2</sup>

<sup>1</sup>Department of Dermatology, Mahatma Gandhi Medical College and Research Institute Sri Balaji Vidyapeeth, Puducherry, <sup>2</sup>Department of Dermatology Venereology and Leprosy, National Institute of Medical Sciences and Research, Jaipur, Rajasthan, India.



**\*Corresponding author:**

Rajendra Devanda,  
Department of Dermatology  
Venereology and Leprosy,  
National Institute of Medical  
Sciences and Research, Jaipur,  
Rajasthan, India.

[rdevanda24@gmail.com](mailto:rdevanda24@gmail.com)

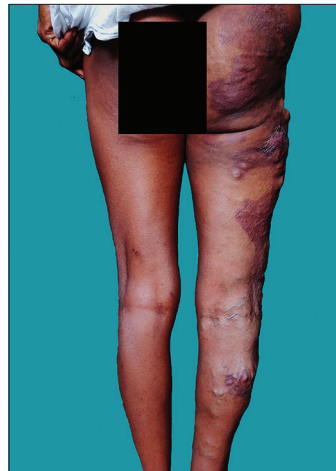Received: 30 September 2023  
Accepted: 25 October 2023  
Published: 03 November 2023

DOI  
10.25259/CSDM\_200\_2023

**Quick Response Code:**



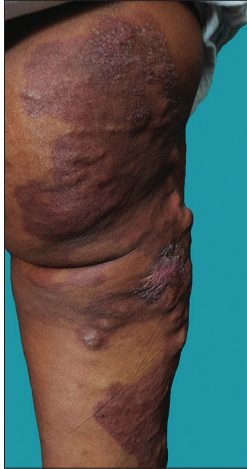
A 29-year-old female presented to the dermatology outpatient department with a reddish stain over her right buttock, thigh, and leg since birth. The patient started developing nodularity around the stain during early childhood. She had intermittent pain over the stain and nodular areas. On cutaneous examination, limb length abnormality was present with a longer right limb than the left. The right thigh, leg, and foot girth were higher than the left side. Non-blanchable dull erythematous stain with a geographical margin extending from the right buttock to the right midcalf was present [Figure 1]. Grouped papules and vesicles with frog spawn appearance were present over the right buttock. Dilated and tortuous veins were noted over the right buttock, posterolateral thigh, and leg, extending to the right foot's dorsal aspect [Figures 1 and 2]. Patients had no other comorbidities. Genetic testing was not done as the facility for it was not available. Thus, a diagnosis of Klippel–Trenaunay syndrome (KTS) was made based on history and clinical



**Figure 1:** Non-blanchable dull erythematous stain with a geographical margin noted extending from the right buttock to the right midcalf. Dilated and tortuous veins were noted over the right buttock and posterolateral thigh extending to the leg.

This is an open-access article distributed under the terms of the Creative Commons Attribution-Non Commercial-Share Alike 4.0 License, which allows others to remix, transform, and build upon the work non-commercially, as long as the author is credited and the new creations are licensed under the identical terms.

©2023 Published by Scientific Scholar on behalf of CosmoDerma



**Figure 2:** Grouped papules and vesicles with frog spawn appearance present over the right buttock. Dilated and tortuous veins were noted over the right buttock and posterolateral thigh.

examination. The patient was advised elastic compression stockings, limb elevation, avoid prolonged standing, and 6 monthly follow-up to detect any complications. KTS is a complex vascular malformation due to a mutation in the PIK3CA gene associated with capillary malformation, venous malformation, and overgrowth of the involved limb. Lymphatic malformation may be associated with KTS.<sup>[1]</sup>

### **Declaration of patient consent**

Patient's consent is not required as patient's identity is not disclosed or compromised.

### **Financial support and sponsorship**

Nil.

### **Conflicts of interest**

There are no conflicts of interest.

### **Use of artificial intelligence (AI)-assisted technology for manuscript preparation**

The authors confirm that there was no use of artificial intelligence (AI)-assisted technology for assisting in the writing or editing of the manuscript and no images were manipulated using AI.

### **REFERENCE**

1. Anderson KR, Nguyen H, Schoch JJ, Lohse CM, Driscoll DJ, Tollefson MM. Skin-related complications of Klippel-Trenaunay syndrome: A retrospective review of 410 patients. *J Eur Acad Dermatol Venereol* 2021;35:517-22.

**How to cite this article:** Couppoussamy K, Devanda R. Klippel–Trenaunay syndrome. *CosmoDerma* 2023;3:162.