

Innovations

Pickaxe and marked hypodermic needle for comedone prick incision

Muhammed Mukhtar

Mukhtar Skin Centre, Katihar Medical College Road, Katihar, Bihar, India.



***Corresponding author:**

Muhammed Mukhtar,
Katihar Medical College Road,
Katihar - 854 105, Bihar, India.

drmmukhtar20@gmail.com

Received : 29 October 2022
Accepted : 08 November 2022
Published : 19 November 2022

DOI
10.25259/CSDM_132_2022

Videos available online at
[https://doi.org/10.25259/
CSDM_132_2022](https://doi.org/10.25259/CSDM_132_2022)

Quick Response Code:

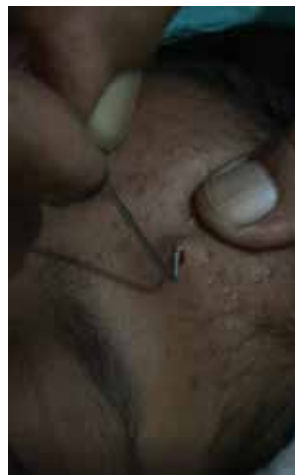

PROBLEM

A hypodermic needle prick incision is routinely used to extract the contents of acne comedone and like structures. Pricking the lesion with a needle is simple because it is done using the needle's tip. However, an incision with the tip is more difficult if it is not vertically aligned with the beveled edge of the needle. In addition, if the plane of the needle's beveled edge has not been marked before making prick incision, we must pay close attention to it.

SOLUTION

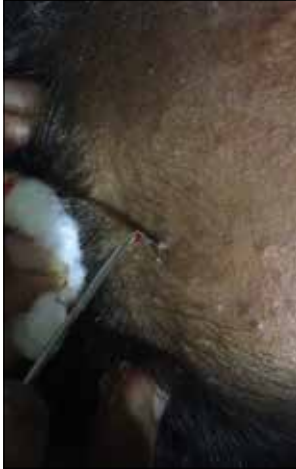The tip and its beveled edge are bent, to ensure the prick incision is in a vertical plane. The bent in the needle is made with a needle holder. It now resembles a pickaxe needle after being modified. Comedones may be easily pierced and incised with this needle by drawing it up and forward [Videos 1 and 2]. As an alternative, after positioning the beveled edge in the vertical position



Video 1: The pickaxe hypodermic needle is used for prick incision over comedone.

This is an open-access article distributed under the terms of the Creative Commons Attribution-Non Commercial-Share Alike 4.0 License, which allows others to remix, transform, and build upon the work non-commercially, as long as the author is credited and the new creations are licensed under the identical terms.

©2022 Published by Scientific Scholar on behalf of CosmoDerma



Video 2: The pickaxe hypodermic needle is used to prick and extract the comedone.

plane, mark the needle's hub. As a result, the modified pickaxe or marked needle may be used for simple prick incision without trouble or confusion [Figure 1a and b].

Declaration of patient consent

Patient's consent not required as there are no patients in this study.

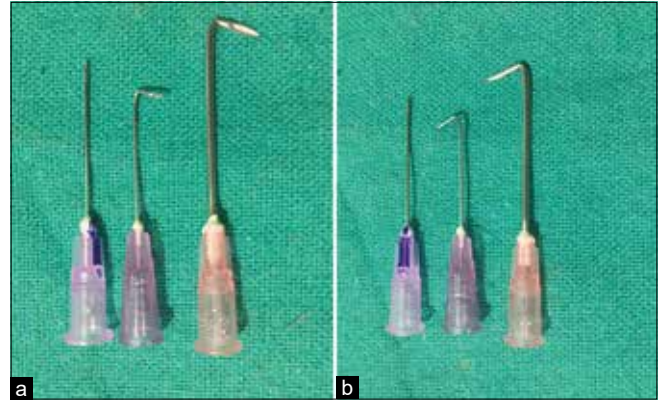


Figure 1: (a and b) The beveled and its opposite planes of the needle (18 and 23G).

Financial support and sponsorship

Nil.

Conflicts of interest

There are no conflicts of interest.

How to cite this article: Mukhtar M. Pickaxe and marked hypodermic needle for comedone prick incision. *CosmoDerma* 2022;2:116.