

Visual Treats in Dermatology

Periorifical dermatitis

Kanupriya Kapil¹, Vishwender Singh¹

¹Department of Dermatology, Venereology and Leprosy, Vardhman Mahavir Medical College, Opposite AIIMS Hospital, New Delhi, India.



***Corresponding author:**

Kanupriya Kapil,
Department of Dermatology,
Venereology and Leprosy,
Vardhman Mahavir Medical
College, Opposite AIIMS
Hospital, New Delhi, India.
priya1kanu.kk@gmail.com

Received : 22 December 2022
Accepted : 21 January 2023
Published : 03 February 2023

DOI
10.25259/CSDM_169_2022

Quick Response Code:



An 18-year-old healthy female presented with multiple grouped tiny red raised skin lesions on her face around mouth and nares for 1 month, associated with mild itching. She had a history of application of topical betamethasone valerate (0.1% w/w) cream twice daily for skin brightening, taken over the counter over her face for the past 1 year. Cutaneous examination revealed multiple, discrete, grouped erythematous papulopustular, and papulovesicular lesions, with loose fine whitish scaling and surrounding erythema on her face in perioral and perinasal distribution, with characteristic sparing of skin adjoining the vermilion border of lips [Figure 1]. Dermoscopy revealed reddish background erythema, prominent follicular openings, and superficial white and yellow scales [Figure 2]. Gram stain and potassium hydroxide mount were negative. She was diagnosed with periorifical facial dermatitis, probably initiated and exacerbated by

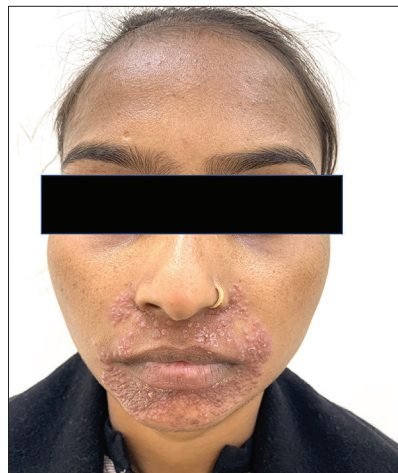

Figure 1: Note multiple, discrete, grouped erythematous papules, with loose fine whitish scaling and surrounding erythema in perioral and perinasal distribution, with characteristic sparing of skin adjoining the vermilion border of lips.

This is an open-access article distributed under the terms of the Creative Commons Attribution-Non Commercial-Share Alike 4.0 License, which allows others to remix, transform, and build upon the work non-commercially, as long as the author is credited and the new creations are licensed under the identical terms.

©2023 Published by Scientific Scholar on behalf of CosmoDerma

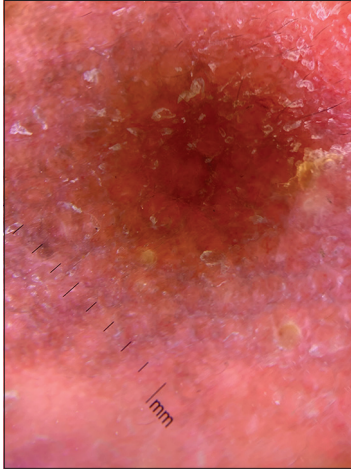


Figure 2: Dermoscopy showing reddish background erythema, prominent follicular openings and superficial white and yellow scales (DermLite DL3N, dry, contact, polarized, $\times 10$).

betamethasone application. She was advised to discontinue steroid application, substituted with topical pimecrolimus 1% cream, and was prescribed oral tetracycline for 8 weeks in a tapering course, along with topical metronidazole 0.75% gel. Her skin eruption resolved with no recurrence as of yet.

Declaration of patient consent

The authors certify that they have obtained all appropriate patient consent.

Financial support and sponsorship

Nil.

Conflicts of interest

There are no conflicts of interest.

How to cite this article: Kapil K, Singh V. Periorificial dermatitis. *CosmoDerma* 2023;3:26.