

Innovations

Chemical sealing of proximal nail fold with cyanoacrylate glue for accelerated regeneration of nail cuticle as a treatment of chronic paronychia

Muhammed Mukhtar¹, Sanjeev Gupta²

¹Department of Dermatology, Mukhtar Skin Centre, Katihar, Bihar, ²Department of Dermatology, MMIMSR, MMDU, Mullana, Ambala, Haryana, India.



***Corresponding author:**

Sanjeev Gupta,
Department of Dermatology,
MMIMSR, MMDU, Mullana,
Ambala, Haryana, India.

sanjeevguptadr@gmail.com

Received: 02 August 2023

Accepted: 18 August 2023

Published: 18 September 2023

DOI

10.25259/CSDM_132_2023

Video available online at:

https://doi.org/10.25259/CSDM_132_2023

Quick Response Code:



PROBLEM

Chronic paronychia is commonly seen in housemakers, maids, and persons engaged in the food industry and involves the loss of cuticles, leading to the formation of a gap between the proximal nail fold (PNF) and nail plate which become a niche for recurrent infections [Figure 1]. The mainstay of treatment is to instruct the patient to refrain from wetting the hands to allow regeneration of the cuticles so that the gap between the PNF and nail plate is obliterated. Unfortunately, it is difficult to refrain from wetting hands during daily chores and this gap persists leading to recurrent infections.

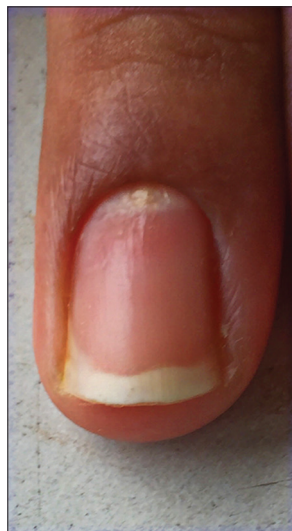


Figure 1: Finger nail showing features of paronychia-loss of cuticle and inflammation of proximal nail fold.

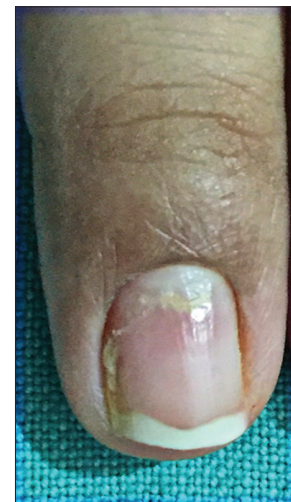
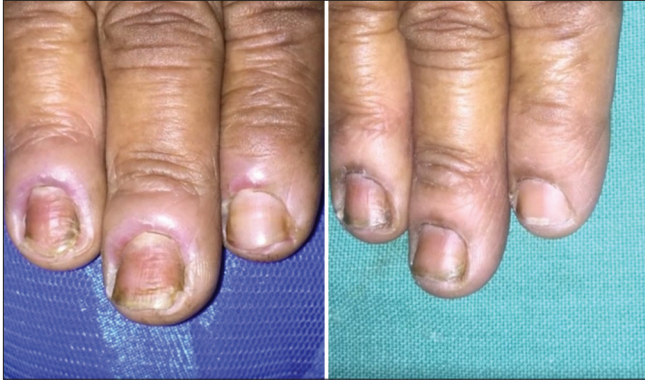
Figure 2: Fingernail showing regeneration of cuticle and gap between proximal nail fold and nail plate is obliterated (Remnants of glue can also be seen).

This is an open-access article distributed under the terms of the Creative Commons Attribution-Non Commercial-Share Alike 4.0 License, which allows others to remix, transform, and build upon the work non-commercially, as long as the author is credited and the new creations are licensed under the identical terms.

©2023 Published by Scientific Scholar on behalf of CosmoDerma



Video 1: Video showing procedural details.

SOLUTION

We tried to overcome this problem using cyanoacrylate glue (after getting a good effect in the cases of hang nails)^[1] to fill this gap between the PNF and the nail plate, thus allowing healing to take place. Depending on the condition, active infection was first controlled with antimicrobials if needed, and the glue was applied under aseptic conditions on the margin of the crevices between the PNF and the nail plate. In addition to its sealant nature, glue is antiseptic and hygroscopic in nature, so it absorbs the remaining moisture from damaged tissue, thus leading to faster healing. The glue remains in place despite the routine wetting of hands. The dried-up glue usually gets dislodged in 2–3 days and can be reapplied by the patient himself at home [Video ppt 1]. This leads to the rapid regeneration of healthy cuticles. We have observed that the gap heals and fills up within 6–8 weeks and provides relief from the condition [Figure 2]. This technique is simple, economical, readily available, and amenable to easy

compliance by the patient and may be an optimal remedy for chronic paronychia in addition to the conventional treatment.

Declaration of patient consent

Patient's consent not required as patients identity is not disclosed or compromised.

Financial support and sponsorship

Nil.

Conflicts of interest

There are no conflicts of interest.

Use of artificial intelligence (AI)-assisted technology for manuscript preparation

The authors confirm that there was no use of Artificial Intelligence (AI)-Assisted Technology for assisting in the writing or editing of the manuscript and no images were manipulated using the AI.

REFERENCE

1. Jangra RS, Gupta S, Singal A, Kaushik A. Hangnail: A simple solution to a common problem. *J Am Acad Dermatol* 2019;81:e123-5.

How to cite this article: Mukhtar M, Gupta S. Chemical sealing of proximal nail fold with cyanoacrylate glue for accelerated regeneration of nail cuticle as a treatment of chronic paronychia. *CosmoDerma* 2023;3:122.