

Visual Treats in Dermatology

Phacomatosis pigmentovascularis

Arun Somasundaram¹

¹Department of Dermatology, Jawaharlal Institute of Postgraduate Medical Education and Research, Puducherry, India.



***Corresponding author:**

Arun Somasundaram,
Department of Dermatology,
Jawaharlal Institute of
Postgraduate Medical
Education and Research,
Puducherry, India.

arunsomasundaram25@gmail.com

Received: 21 September 2023

Accepted: 16 October 2023

Published: 07 December 2023

DOI

10.25259/CSDM_189_2023

Quick Response Code:



A 5-year-old male child was brought by parents with complaints of skin lesions that present since birth over the face and back. The child was born of a non-consanguineous marriage with uneventful antenatal and natal history. The child was developmentally normal. Cutaneous examination revealed a port-wine stain over the face associated with mild hypertrophy of the upper lip [Figure 1a] and aberrant extensive Mongolian spots (dermal melanocytosis) over the back and leg [Figure 1b]. The child was diagnosed with phacomatosis pigmentovascularis type 2 (association of the nevus flammeus and aberrant Mongolian spots). Our child did not have any neurological or eye and skeletal concerns. Magnetic resonance imaging and magnetic resonance angiography did not reveal any abnormalities. Parents were reassured regarding the condition and were advised to follow-up later if required.

Phacomatosis pigmentovascularis is orchestrated by an association of a vascular nevus with an extensive pigmentary nevus. Hasegawa and Yasuhara classified into five types and each type was further subdivided according to the presence of cutaneous-only manifestations (subtype a) or if associated with systemic manifestations (subtype b), which are ocular, vascular, skeletal, and neurological. Happle classified into four groups – phacomatosis cesioflamea (nevus flammeus and aberrant Mongolian spots or blue nevus), phacomatosis spilorosea (nevus spilus and telangiectatic

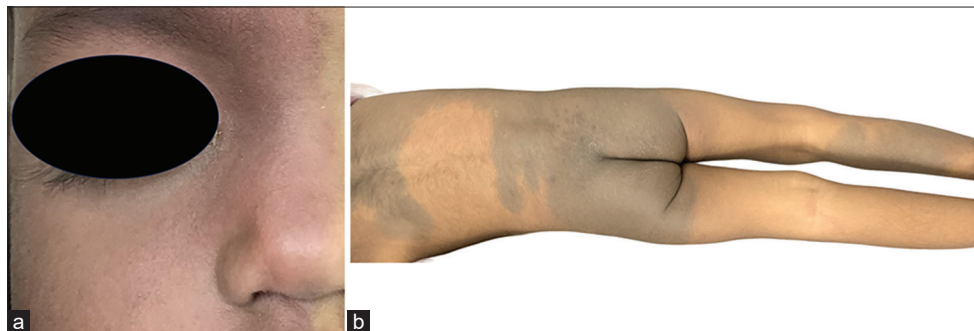


Figure 1: (a) Port-wine stain over the face associated with mild hypertrophy of the upper lip. (b) Aberrant extensive Mongolian spots (dermal melanocytosis) over the back.

nevus), phacomatosis cesiomarmorata (aberrant Mongolian spots or blue nevus with cutis marmorata telangiectatica congenita), and phacomatosis pigmentovascularis of non-classifiable type.^[1] Magnetic resonance imaging, magnetic resonance angiography and venography of the brain, echocardiogram, detailed eye examination, and skeletal survey are to be done if the organ system is clinically suspected to be affected. This case highlights the importance of screening for associated neurological, ocular, and skeletal abnormalities in a child with phacomatosis pigmentovascularis. Though, our child had extensive skin lesions was found to have no extracutaneous involvement.

Declaration of patient consent

The authors certify that they have obtained all appropriate patient consent.

Financial support and sponsorship

Nil.

Conflicts of interest

There are no conflicts of interest.

Use of artificial intelligence (AI)-assisted technology for manuscript preparation

The author confirms that there was no use of artificial intelligence (AI)-assisted technology for assisting in the writing or editing of the manuscript and no images were manipulated using AI.

REFERENCE

1. Nanda A, Al-Abdulrazzaq HK, Habeeb YK, Zakkiriah M, Alghadhfan F, Al-Noun R, *et al.* Phacomatosis pigmentovascularis: Report of four new cases. *Indian J Dermatol Venereol Leprol* 2016;82:298-303.

How to cite this article: Somasundaram A. Phacomatosis pigmentovascularis. *CosmoDerma* 2023;3:173. doi: 10.25259/CSDM_189_2023