

## Visual Treats in Dermatology

# Non-syndromic woolly hair in a child

Arun Somasundaram<sup>1</sup>, Sanath Aithal<sup>1</sup>

<sup>1</sup>Department of Dermatology, KMCH Institute of Health Sciences and Research, Coimbatore, Tamil Nadu, India.



**\*Corresponding author:**

Arun Somasundaram,  
Department of Dermatology,  
KMCH Institute of Health  
Sciences and Research,  
Coimbatore, Tamil Nadu, India.  
arunsomasundaram25@gmail.  
com

Received: 11 August 2023  
Accepted: 23 August 2023  
Published: 01 September 2023

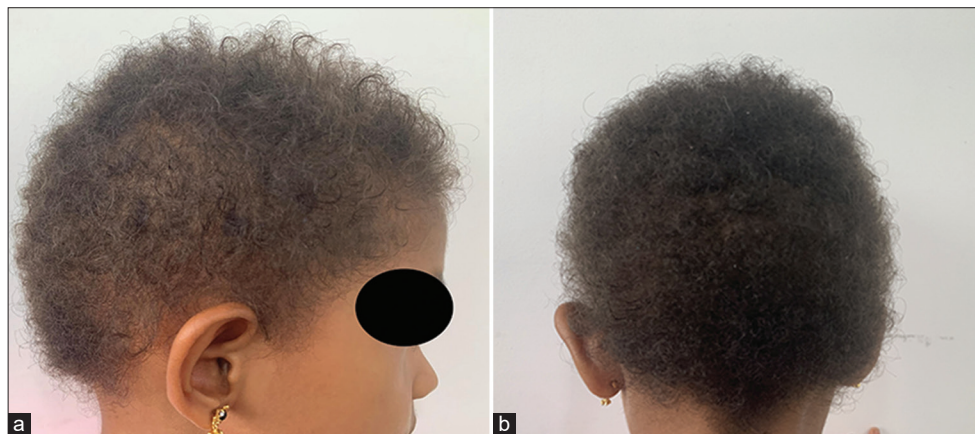
DOI  
10.25259/CSDM\_141\_2023

**Quick Response Code:**



A 6-year-old female child accompanied by her mother presented with complaints of progressive curling of scalp hair since 1 year of life. The child was born of a non-consanguineous marriage with no known or distant African ancestry. There was no family history of similar complaints. The child was otherwise systemically well. On examination, the hair all over the scalp was found to be brown, sparse, unruly, frizzy, short, curly, and brittle suggestive of woolly hair [Figure 1a and b]. The child did not have palmoplantar keratoderma. The rest of the cutaneous and mucosal examination was noncontributory. The child did not have any dental, ocular, or skeletal abnormalities. Echocardiography was done which did not reveal any evidence of cardiomyopathy. Hence, a clinical diagnosis of a non-syndromic variant of woolly hair was considered, and further, confirmation by genetic testing was advised; however, mother wanted to get it done at a later date.

Woolly hair can be a manifestation of a systemic disease (syndromic) or in the absence of systemic findings (non-syndromic). Three types described in the literature include autosomal dominant (hereditary woolly hair), autosomal recessive, and localized woolly hair nevus. Characteristic associations include Naxos disease and Carvajal syndrome presenting with dilated cardiomyopathy, woolly hair, and palmoplantar keratoderma. Woolly hair has also been associated with enamel hypoplasia, ocular defects, deafness and ichthyosis vulgaris, keratosis



**Figure 1:** (a and b) 6-year-old female child with unruly frizzled brown colored hair suggestive of woolly hair.

This is an open-access article distributed under the terms of the Creative Commons Attribution-Non Commercial-Share Alike 4.0 License, which allows others to remix, transform, and build upon the work non-commercially, as long as the author is credited and the new creations are licensed under the identical terms.

©2023 Published by Scientific Scholar on behalf of CosmoDerma

pilaris atrophicans, and Noonan syndrome.<sup>[1]</sup> Visually identifying this entity is important to rule out associations and manage the child accordingly.

#### **Declaration of patient consent**

The authors certify that they have obtained all appropriate patient consent.

#### **Financial support and sponsorship**

Nil.

#### **Conflicts of interest**

There are no conflicts of interest.

#### **Use of artificial intelligence (AI)-assisted technology for manuscript preparation**

The authors confirm that there was no use of Artificial Intelligence (AI)-Assisted Technology for assisting in the writing or editing of the manuscript and no images were manipulated using AI.

#### **REFERENCE**

1. Jabeen M, Kaur G, Sharma E, Dogra D. Twisted tresses a rare case series of familial woolly hair. *Int J Contemp Pediatr* 2022;9:202-4.

**How to cite this article:** Somasundaram A, Aithal S. Non-syndromic woolly hair in a child. *CosmoDerma* 2023;3:119.