

Images/Instrument in Dermatology/Dermatosurgery

Kerion celsi caused by *Trichophyton mentagrophytes*: Clinical, trichoscopic, and microscopic features

Gaby Lalmuanpuui¹, Krishna Deb Barman¹, Shukla Das², Vishal Gaurav¹

¹Department of Dermatology and Venereology, Maulana Azad Medical College, New Delhi, ²Department of Microbiology, University College of Medical Sciences, Delhi, India.



***Corresponding author:**

Vishal Gaurav,
Department of Dermatology
and Venereology, Maulana
Azad Medical College,
New Delhi, India.

mevishalgaurav@gmail.com

Received: 19 May 2024

Accepted: 06 June 2024

Published: 02 July 2024

DOI

10.25259/CSDM_69_2024

Quick Response Code:



A 6-year-old boy presented with a single painful boggy swelling with overlying hair loss on the scalp for two weeks. On examination, there was a single, well-defined, erythematous, fluctuant nodular swelling over the mid-frontal scalp measuring 4 × 4 cm, with multiple follicular pustules, semi-adherent yellowish-white crusts, peripheral white scales, and overlying alopecia [Figure 1] without any regional lymphadenopathy. Trichoscopy revealed multiple yellow globules, few pigtail, corkscrew as well as morse code hair, and black dots along with hemorrhage [Figure 2], over a background of erythema. Microscopy of potassium hydroxide (KOH) mount of a plucked hair revealed intrapillary arthroconidia [Figure 3]. *Trichophyton mentagrophytes* complex was isolated on culture in Sabouraud dextrose agar at 25° C. Lactophenol cotton blue mount from the culture showed spiral hyphae [Figure 4]. Based on the clinical, trichoscopic, and microscopy features, a diagnosis of kerion caused by *T. mentagrophytes* was made and the patient was started

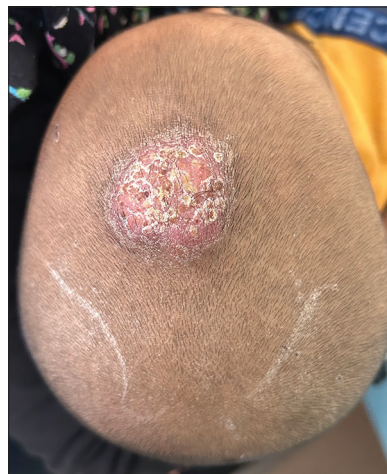

Figure 1: Single, well-defined, erythematous nodular swelling over the mid-frontal scalp measuring 4 × 4 cm, with multiple follicular pustules, semi-adherent yellowish-white crusts, peripheral white scales, and overlying alopecia.

This is an open-access article distributed under the terms of the Creative Commons Attribution-Non Commercial-Share Alike 4.0 License, which allows others to remix, transform, and build upon the work non-commercially, as long as the author is credited and the new creations are licensed under the identical terms.

©2024 Published by Scientific Scholar on behalf of CosmoDerma




Figure 2: Trichoscopic examination in polarized mode (Heine DELTAone) at $\times 10$ magnification showing multiple yellow globules (yellow circles), few pigtail (navy blue circle), corkscrew (red circle) as well as morse code hair (orange circle), and black dots (red arrows) along with hemorrhage (green circle), over a background of erythema.

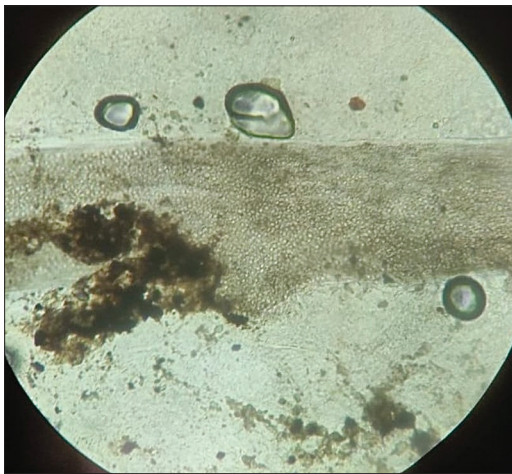

Figure 3: Microscopy of potassium hydroxide mount of a plucked hair showing intrapillary arthroconidia ($\times 400$).

on oral griseofulvin microsize suspension at a dose of 20 mg/kg for 6 weeks. However, the response to therapy could not be assessed as the patient was lost to follow-up.

Kerion, an inflammatory tinea capitis, presents as boggy, tender nodules with pustules, scaling, alopecia, and regional lymphadenopathy, mostly in children. Common causative agents include *Trichophyton tonsurans* and *Microsporum canis*, with *T. mentagrophytes* being uncommon.^[1] Diagnosis involves

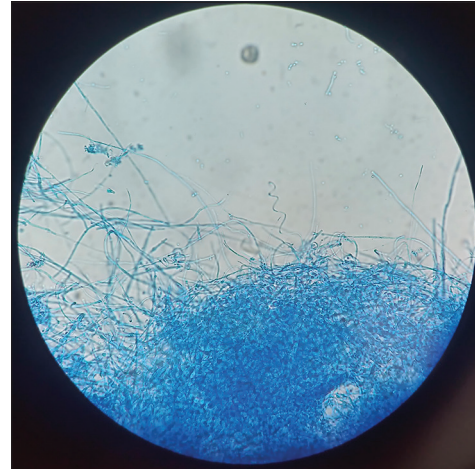

Figure 4: Microscopy of lactophenol cotton blue mount from the culture on Sabouraud dextrose agar at 25° C showing spiral hyphae ($\times 100$).

dermoscopy showing yellow dots, comma hairs, and corkscrew hairs, and KOH microscopy revealing arthroconidia and septate hyphae.^[2] Treatment with oral antifungals (griseofulvin, terbinafine, and itraconazole) is essential to prevent scarring alopecia. Prognosis is generally good with timely intervention.^[1]

Ethical approval

The Institutional Review Board approval is not required.

Declaration of patient consent

The authors certify that they have obtained all appropriate patient consent.

Conflict of interest

There are no conflicts of interest.

Financial support and sponsorship

Nil.

Use of artificial intelligence (AI)-assisted technology for manuscript preparation

The authors confirm that there was no use of artificial intelligence (AI)-assisted technology for assisting in the writing or editing of the manuscript and no images were manipulated using AI.

REFERENCES

1. Chiriac A, Diaconeasa A, Voicu C, Ivaniciuc M, Miulescu R, Chiriac AE, et al. Kerion Celsi in infants and children-A narrative review 2010-2023. *Mycoses* 2024;67:e13675.

2. Pirmez R. The dermatoscope in the hair clinic: Trichoscopy of scarring and nonscarring alopecia. *J Am Acad Dermatol* 2023;89:S9-15.

How to cite this article: Lalmuanpuii G, Barman KD, Das S, Gaurav V. Kerion celsi caused by *Trichophyton mentagrophytes*: Clinical, trichoscopic, and microscopic features. *CosmoDerma*. 2024;4:70. doi: 10.25259/CSDM_69_2024