

Visual Treats in Dermatology

Lichen nitidus with koebnerization

Avita Dhiman¹, Manju Daroach¹

¹Department of Dermatology, All India Institute of Medical Sciences Bilaspur, Bilaspur, Himachal Pradesh, India.



***Corresponding author:**

Manju Daroach,
Department of Dermatology,
All India Institute of Medical
Sciences Bilaspur, Bilaspur,
Himachal Pradesh, India.

dr.manju.derma@aiimbilaspur.edu.in

Received : 31 May 2023
Accepted : 13 June 2023
Published : 21 June 2023

DOI
10.25259/CSDM_113_2023

Quick Response Code:



A 10-year-old girl presented with multiple slightly pruritic lesions over upper limbs, neck, and trunk. On examination, there were multiple shiny flat-topped hypopigmented to mildly violaceous papules few present in linear pattern exhibiting Koebner phenomenon (black arrow) distributed over above mentioned sites [Figure 1]. Dermoscopy [Figure 2] demonstrates multiple, white, and well-defined circular areas (black arrow) with whitish scales (yellow arrow) along with central brown shadow (red arrow) within white circular areas which are a dermoscopic marker and alleviate the need for biopsy in children.

Lichen nitidus is a benign skin condition characterized by the presence of tiny, flat-topped, and skin-colored papules.^[1] Typical histology includes “claw and ball appearance.”^[1] The differential diagnosis for this condition includes lichen planus, verruca, lichen spinulosus and phrynoderma, and keratosis pilaris.^[2]

Treatment options include topical corticosteroids; topical calcineurin inhibitors may be prescribed to reduce inflammation and itching. Phototherapy and oral medications such as

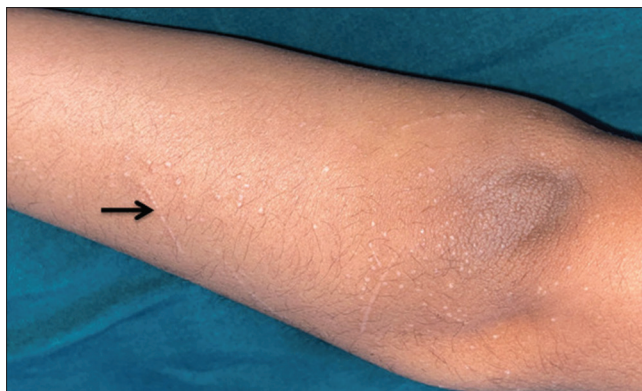

Figure 1: Multiple shiny flat-topped hypopigmented to mildly violaceous papules few present in linear pattern exhibiting Koebner (black arrow) phenomenon over upper limbs, trunk, and neck.

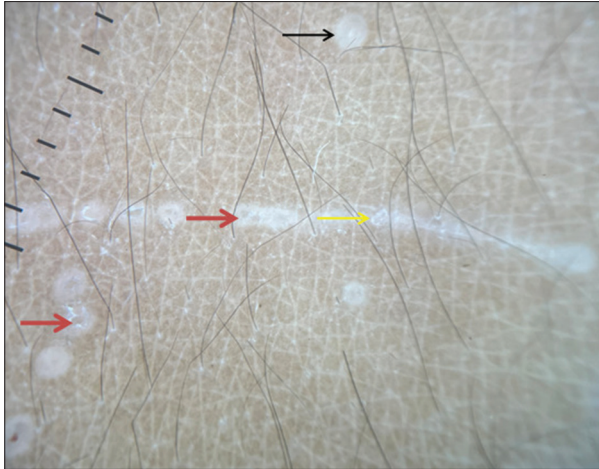


Figure 2: Dermoscopy (DermLite DL4; 3Gen; San Juan Capistrano, California, USA, noncontact polarized mode, $\times 10$ magnification) showed multiple, white, and well-circular areas (black arrow) with whitish scales (yellow arrow), along with central brown shadow (red arrow) within white circular areas.

steroids, acitretin, low-dose cyclosporine, and itraconazole may also be considered in more severe or widespread cases.^[2]

Declaration of patient consent

The authors certify that they have obtained all appropriate patient consent.

Financial support and sponsorship

Nil.

Conflicts of interest

There are no conflicts of interest.

REFERENCES

1. Schwartz C, Goodman MB. Lichen nitidus. In: StatPearls. Treasure Island, FL: StatPearls Publishing; 2023.
2. Mangold AR, Pittelkow MR. Lichen nitidus and lichen striatus. In: Fitzpatrick's Dermatology. 9th ed. United States: McGraw-Hill Education; 2019. p. 554-8.

How to cite this article: Dhiman A, Daroach M. Lichen nitidus with koebnerization. *CosmoDerma* 2023;3:101.