

Letter to the Editor

## Palmoplantar keratoderma and woolly hair

Tanshum Kalyana<sup>1</sup>, Astha Arora<sup>1</sup>, G. P. Thami<sup>1</sup>

<sup>1</sup>Department of Dermatology, Venereology and Leprosy, Government Medical College and Hospital, Chandigarh, India.



**\*Corresponding author:**

Astha Arora,  
Department of Dermatology,  
Venereology and Leprosy,  
Government Medical College  
and Hospital, Chandigarh,  
Chandigarh, India.

astharora912@gmail.com

Received : 12 September 2022

Accepted : 28 September 2022

Published : 12 October 2022

**DOI**

10.25259/CSDM\_98\_2022

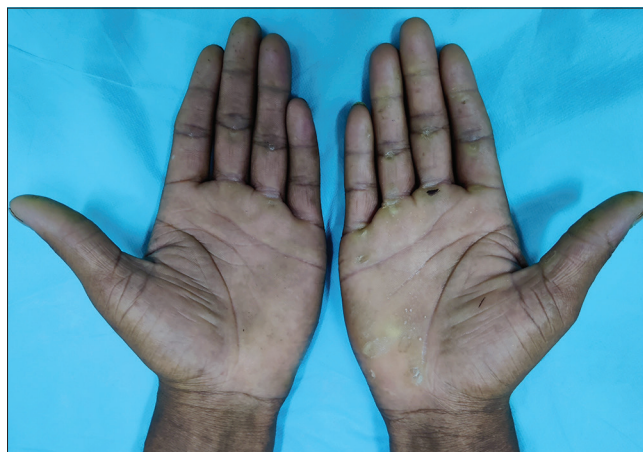**Quick Response Code:**



Dear Sir,

We report a case of a 23-year-old male who presented with palmoplantar keratoderma (PPK) making it difficult for him to walk and perform his daily activities due to stiffness of skin of palms with associated pitted keratolysis present on bilateral soles [Figures 1 and 2]. On close observation, coarse curly hair was noticed over the scalp [Figure 3a and b]. The patient was accompanied by his brother whose hair texture differed from that of patient but their sister reportedly had curly coarse hair. There were no complaints in his parents. On hair light microscopy, hair shafts were flat and irregular [Figure 4]. The patient was further investigated and ECG changes were consistent with fascicular ventricular tachycardia with the right bundle branch block pattern and 2D echocardiography showed right ventricular cardiomyopathy. Routine investigations were normal. The patient was counseled and symptomatically managed for PPK.

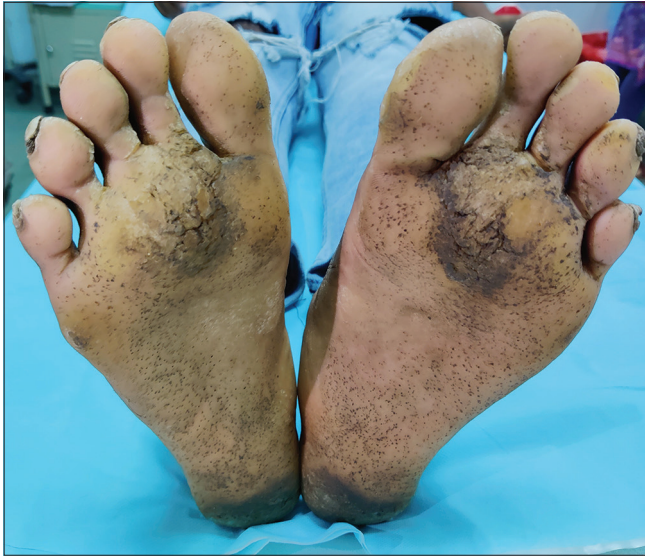PPK is a heterogeneous group of genodermatosis, with hyperkeratosis of palms and soles. They are classified according to either their morphology (diffuse, focal, and punctate), mode of inheritance (autosomal dominant and autosomal recessive), and presence or absence of extracutaneous features. The classical clinical presentation of PPK, right ventricular cardiomyopathy, and woolly hair establishes the diagnosis of diffuse inherited PPK with extracutaneous features, most likely of Naxos disease, caused by mutation in plakoglobin gene. Therefore, whenever woolly hair presented with associated PPK, search for possible cardiac abnormalities is recommended, and regular follow-up is required.<sup>[1]</sup> Naxos disease is a rare genodermatosis with woolly hair, PPK, and



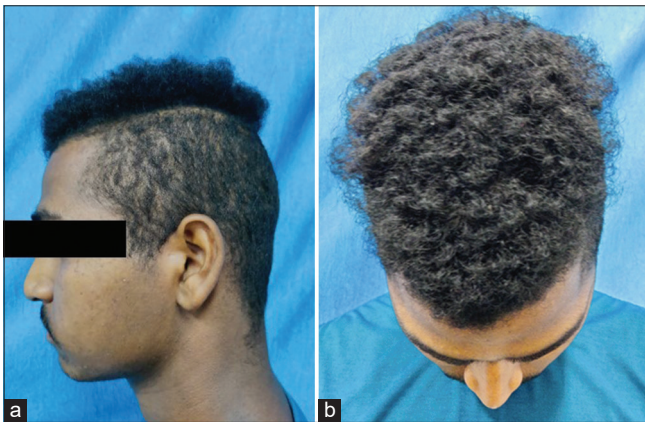**Figure 1:** Palmar keratoderma with callosities.

This is an open-access article distributed under the terms of the Creative Commons Attribution-Non Commercial-Share Alike 4.0 License, which allows others to remix, transform, and build upon the work non-commercially, as long as the author is credited and the new creations are licensed under the identical terms.

©2022 Published by Scientific Scholar on behalf of CosmoDerma

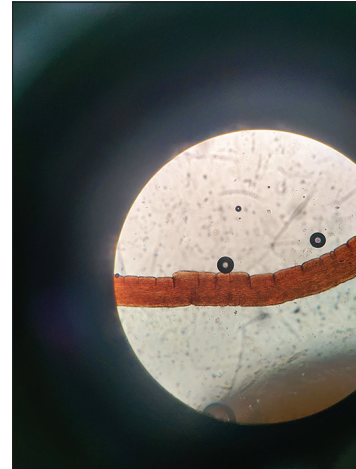


**Figure 2:** Plantar keratoderma with pitted keratolysis.



**Figure 3:** (a and b) Curly coarse hairs suggestive of woolly hair (lateral view).

cardiomyopathy.<sup>[2]</sup> In India, there are very few case reports on Naxos disease, which comes in view when the patient comes with recurrent syncope or rhythm abnormalities, so regular monitoring is required.



**Figure 4:** Hair microscopy (40 ×) showing flat and irregular hair shaft.

#### **Declaration of patient consent**

The authors certify that they have obtained all appropriate patient consent.

#### **Financial support and sponsorship**

Nil.

#### **Conflicts of interest**

There are no conflicts of interest.

#### **REFERENCES**

1. Meera G, Prabhavathy D, Jayakumar S, Tharini GK. Naxos disease in two siblings. *Int J Trichology* 2010;2:53-5.
2. Rai R, Ramachandran B, Sundaram VS, Rajendren G, Srinivas CR. Naxos disease: A rare occurrence of cardiomyopathy with woolly hair and palmoplantar keratoderma. *Indian J Dermatol Venereol Leprol* 2008;74:50-2.

**How to cite this article:** Kalyana T, Arora A, Thami GP. Palmoplantar keratoderma and woolly hair. *CosmoDerma* 2022;2:91.