

Visual Treats in Dermatology

Psoriasis associated with vitiligo universalis and photosensitive rash

Konsam Nirupama Devi¹, Priyanka Sangwan¹

¹Department of Dermatology, Venereology and Leprosy, All India Institute of Medical Sciences, Rishikesh, Uttarakhand, India.



***Corresponding author:**
 Konsam Nirupama Devi,
 Department of Dermatology,
 Venereology and Leprosy,
 All India Institute of
 Medical Sciences, Rishikesh,
 Uttarakhand, India.
 nirupama.konsam@gmail.com

Received : 22 July 2022
 Accepted : 26 August 2022
 Published : 05 September 2022

DOI
 10.25259/CSDM_72_2022

Quick Response Code:



A 35-year-old-female presented with itchy, reddish, and scaly lesions over the body for the past 5 months, she also gave history of whitish lesions all over the body for the past 25 years. Cutaneous examination revealed multiple, well-defined, erythematous, and indurated plaques with silvery scales over extensor aspects of bilateral upper and lower limbs, trunk, and scalp (body surface area ~8%) [Figure 1a and b]. Depigmentation all over the body with eyebrows and frontal hair involvement and discrete hyperpigmented skin macules on the face was also noted [Figure 1c]. There was photosensitive rash on the face, extending on to the V area of neck and upper back [Figure 1b and c]. Ophthalmology reference was sought and ocular albinism was ruled out.

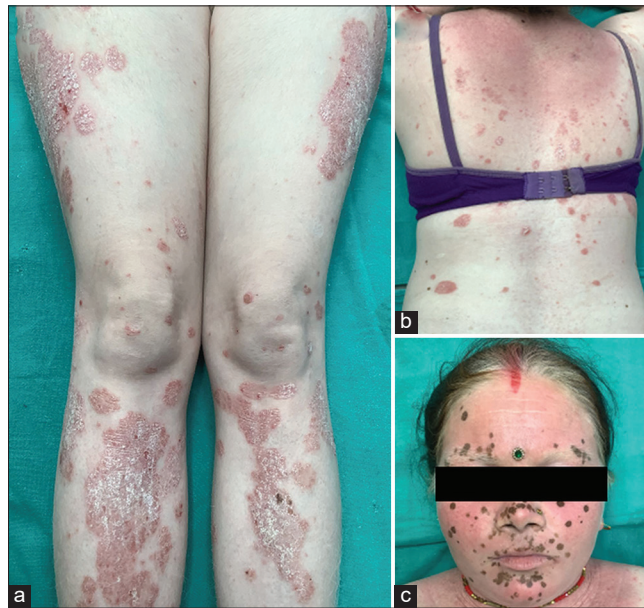


Figure 1: (a). Erythematous indurated plaques with silvery scales on a background of depigmented lesions on the extensor aspects of bilateral lower limbs (b). Erythematous indurated plaques with silvery scales on a background of depigmented lesions on the back and photosensitive rash on the upper back (c). Discrete hyperpigmented skin macules and photosensitive rash on the face.

This is an open-access article distributed under the terms of the Creative Commons Attribution-Non Commercial-Share Alike 4.0 License, which allows others to remix, transform, and build upon the work non-commercially, as long as the author is credited and the new creations are licensed under the identical terms.

©2022 Published by Scientific Scholar on behalf of CosmoDerma

A diagnosis of plaque psoriasis with vitiligo universalis and photosensitive rash was arrived at. The patient was advised photoprotection; and for psoriasis, she was given oral antihistamines, combined clobetasol 0.05% and salicylic acid 6% ointment once daily and emollients for cutaneous lesions on body; combined halobetasol 0.05% and salicylic acid 3% lotion, and ketoconazole 2% shampoo for scalp lesions. She did not want treatment for vitiligo. Although various studies reported association of vitiligo with psoriasis,^[1] we hereby report a case of psoriasis in pre-existing vitiligo universalis with photosensitive rash.

Declaration of patient consent

The authors certify that they have obtained all appropriate patient consent.

Financial support and sponsorship

Nil.

Conflicts of interest

There are no conflicts of interest.

REFERENCE

1. Percivalle S, Piccinno R, Caccialanza M. Concurrence of vitiligo and psoriasis: A simple coincidence? Clin Exp Dermatol 2009;34:90-1.

How to cite this article: Devi KN, Sangwan P. Psoriasis associated with vitiligo universalis and photosensitive rash. CosmoDerma 2022;2:69.