

Letter to the Editor

## Disseminated cutaneous rhinosporidiosis in an immunocompetent patient with varied morphology

Reshma Vijayakumaran Sukumari<sup>1</sup>, Pradeep S. Nair<sup>2</sup>

<sup>1</sup>Department of Dermatology and Venereology, Government TD Medical College, Alappuzha, <sup>2</sup>Department of Dermatology and Venereology, Government Medical College, Trivandrum, Kerala, India.



**\*Corresponding author:**

Pradeep S. Nair,  
Department of Dermatology  
and Venereology, Government  
Medical College, Trivandrum,  
Kerala, India.

dvmchtvm@yahoo.co.in

Received : 20 May 2023

Accepted : 06 June 2023

Published : 21 June 2023

**DOI**

10.25259/CSDM\_110\_2023

**Quick Response Code:**



Dear Sir,

Rhinosporidiosis is a chronic granulomatous disorder caused by *Rhinosporidium seeberi*. It is endemic in South Asia, being mainly reported from Southern India and Sri Lanka. This condition occurs more commonly in adult men who present as a painless, friable, and polypoidal growth involving the nasopharynx in 70% of the cases. Many patients give history of bathing in ponds before the onset of the lesions as the organism is prevalent in stagnant water of ponds. Cutaneous dissemination is very rare and can present with a wide variety of morphological forms.<sup>[1]</sup> Here, we report a case of disseminated cutaneous rhinosporidiosis.

A 54-year-old male presented with 10 years history of reddish friable mass protruding from the right nostril which was associated with nasal block, anosmia, bleeding from nose, and difficulty in swallowing. He had a habit of frequent bathing in nearby ponds. There was history of excision of lesion by an otolaryngologist 6 years back, but the lesions recurred in the same area which was again excised. The past 4 months he noticed multiple asymptomatic raised lesions over the body, with occasional bleeding from the lesions. There were no systemic symptoms and history was unremarkable.

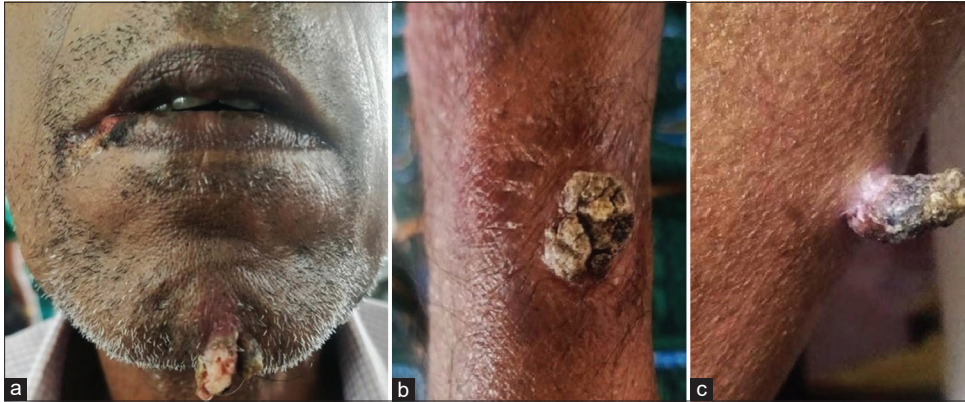On examination, there were multiple discrete pedunculated erythematous, fleshy papules, and plaques with surface showing hemorrhagic crusting was seen on chin, medial aspect of left arm, thigh, and buttocks. The pedunculated papules and plaques on the chin and thigh resembled cutaneous horns [Figure 1a and c] and there were discrete verrucous plaques over left forearm [Figure 1b].

His hemogram, liver and renal function, and blood sugar was within normal limits. Viral markers were negative. A KOH mount test from the skin lesions showed sporangia with endospores [Figure 2]. Excision biopsy of the chin and thigh lesion was sent for histopathology. On gross examination, there were gray-brown with friable tissues. Histopathology showed epidermis with hyperkeratosis, irregular acanthosis packed with multiple sporangia giving a “Swiss cheese appearance” [Figure 3]. High power showed the epidermis filled with sporangia containing numerous endospores [Figure 4]. The dermis showed mixed inflammatory cell infiltrates with congested blood vessels. A final diagnosis of disseminated cutaneous rhinosporidiosis was made. Most of the lesions were surgically excised and the patient was put on dapson 100 mg daily with ciprofloxacin 500 mg twice daily.

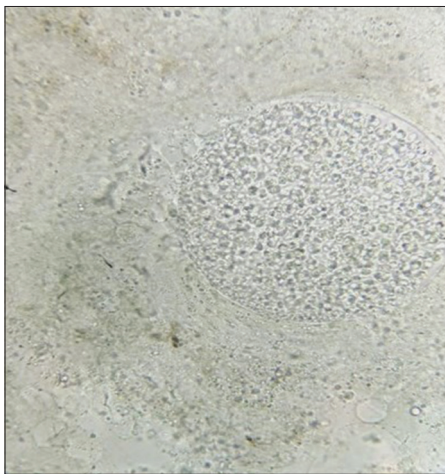
Our patient gave history of frequent bathing in ponds. He gave history of fleshy polypoidal mass on the nasopharynx which was excised. Subsequently, the patient developed multiple pedunculated

This is an open-access article distributed under the terms of the Creative Commons Attribution-Non Commercial-Share Alike 4.0 License, which allows others to remix, transform, and build upon the work non-commercially, as long as the author is credited and the new creations are licensed under the identical terms.

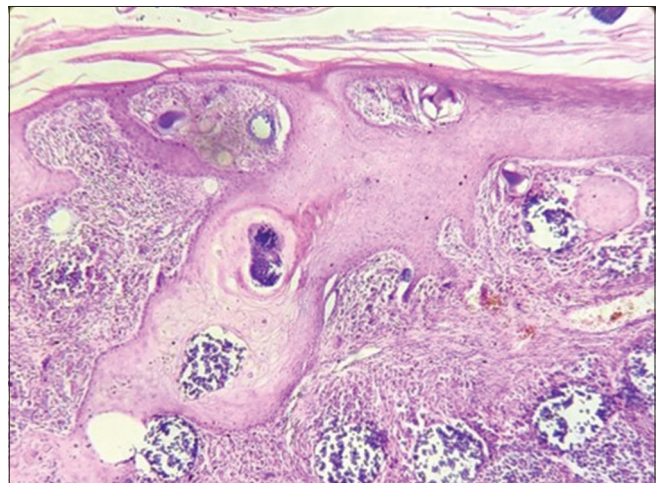
©2023 Published by Scientific Scholar on behalf of CosmoDerma



**Figure 1:** (a) Pedunculated papule on chin resembling cutaneous horn, (b) verrucous plaque on forearm, and (c) cutaneous horn like papule on thigh.



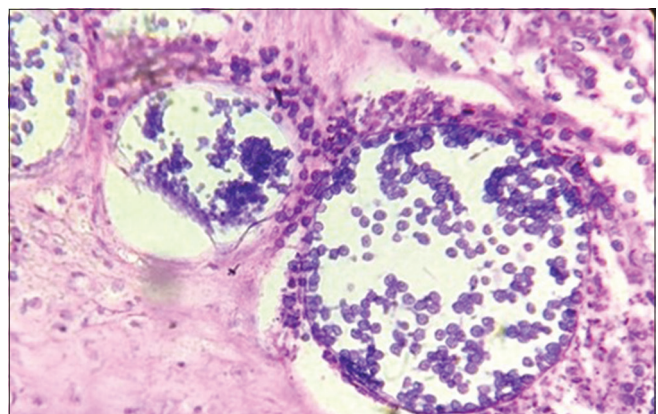
**Figure 2:** 10% KOH mount test showing sporangium with endospores,  $\times 40$ .



**Figure 3:** Skin biopsy showing epidermal hyperplasia with numerous sporangia with "Swiss cheese" appearance, H&E,  $\times 100$ .

papules resembling cutaneous horn on the chin and thighs and verrucous lesions on the limbs. The patient was human immunodeficiency virus (HIV) negative. KOH mount test demonstrated sporangia with endospores. Excision biopsy demonstrated multiple sporangia with endospores in the epidermis. Therefore, we made a diagnosis of disseminated cutaneous rhinosporidiosis with varied morphology.

Rhinosporidiosis originally considered to be a sporozoan is now considered to be a cyanobacterium, *Microcystis aeruginosa* which explains its response to ciprofloxacin.<sup>[2]</sup> The organism is found in the stagnant water of ponds and lakes. The port of entry of the organism is through the mucosa of the nostrils, and hence, it is rampant in people who bath in these ponds. The mode of spread is by autoinoculation, hematogenous dissemination, and direct inoculation (primary cutaneous rhinosporidiosis). In our patient, it was hematogenous dissemination as the patient initially had nasal lesions later followed by lesions on various parts of the body. Moreover, the cutaneous lesions appeared after excision of the nasal lesions, and hence, autoinoculation



**Figure 4:** Skin biopsy (High power) showing sporangia with numerous endospores, H&E,  $\times 400$ .

was ruled out. Disseminated cutaneous rhinosporidiosis has been reported in the context of HIV infection, but our patient was HIV negative. Rhinosporidiosis can be recurrent

**Table 1:** Various cutaneous manifestations of rhinosporidiosis.

Author	Year	Clinical lesions	Distribution	Treatment
Desai and Patil <sup>[3]</sup>	2023	Verrucous lesions	Nose	Radioablation followed by dapsone
Salim and Komu <sup>[4]</sup>	2016	Genitourinary pedunculated mass	External urinary meatus	Radiofrequency ablation with dapsone
Verma <i>et al.</i> <sup>[5]</sup>	2012	Subcutaneous nodules	Limbs	Dapsone
Nayak <i>et al.</i> <sup>[6]</sup>	2007	Globular swellings	Limbs	Dapsone
Ghorpade <sup>[7]</sup>	2006	Giant tumor like lesions	Face, limbs	Excision with amphotericin B
Kumari <i>et al.</i> <sup>[2]</sup>	2005	Furuncle like lesions, cutaneous horn	Face, limbs	Excision, Dapsone
Hadke and Baruah <sup>[8]</sup>	1990	Cutaneous ulceration	Face, limbs	Dapsone
Present case	2023	Cutaneous horn like lesions and verrucous lesions	Chin, arms, and thigh	Surgical excision followed by dapsone

and troublesome. The patient must be advised against taking baths in stagnant ponds to prevent recurrences. The cutaneous manifestations of rhinosporidiosis are protean and can mimic many dermatosis. The papules and plaques are pedunculated or sessile. Clinically, granuloma pyogenicum and Kaposi's sarcoma are the differentials. The various cutaneous manifestations of rhinosporidiosis in Indian patients are given in [Table 1].<sup>[4-8]</sup> Our patient had lesions resembling cutaneous horn and verrucous lesions. Surgical and electrodesiccation are the treatment of choice for localised lesions. Dapsone, ciprofloxacin, ketoconazole, and amphotericin B are the drugs tried.<sup>[3]</sup> We are reporting an interesting case of disseminated cutaneous rhinosporidiosis in an immunocompetent patient presenting with cutaneous horn such as lesions and verrucous lesions.

#### Declaration of patient consent

The authors certify that they have obtained all appropriate patient consent.

#### Financial support and sponsorship

Nil.

#### Conflicts of interest

There are no conflicts of interest.

#### REFERENCES

- Mandal SK, Dutta S, Roy S. Cutaneous rhinosporidiosis. *Indian J Dermatol* 2000;45:78-80.
- Kumari R, Nath AK, Rajalakshmi R, Adityan B, Thappa DM. Disseminated cutaneous rhinosporidiosis: Varied morphological appearances on the skin. *Indian J Dermatol Venereol Leprol* 2009;75:68-71.
- Desai CA, Patil S. Disseminated cutaneous rhinosporidiosis. *Indian J Dermatol Venereol Leprol* 2023;89:71-2.
- Salim T, Komu F. Varied presentations of cutaneous rhinosporidiosis: A report of three cases. *Indian J Dermatol* 2016;61:209-12.
- Verma R, Vasudevan B, Pragasaam V, Deb P, Langer V, Rajagopalan S. A case of disseminated cutaneous rhinosporidiosis presenting with multiple subcutaneous nodules and warty growths. *Indian J Dermatol Venereol Leprol* 2012;78:520.
- Nayak S, Acharjya B, Devi B, Sahoo A, Singh N. Disseminated cutaneous rhinosporidiosis. *Indian J Dermatol Venereol Leprol* 2007;73:185-7.
- Ghorpade A. Polymorphic cutaneous rhinosporidiosis. *Eur J Dermatol* 2006;16:190-2.
- Hadke NS, Baruah MC. Primary cutaneous rhinosporidiosis. *Indian J Dermatol Venereol Leprol* 1990;56:61-3.

**How to cite this article:** Sukumari RV, Nair PS. Disseminated cutaneous rhinosporidiosis in an immunocompetent patient with varied morphology. *CosmoDerma* 2023;3:98.